

Endodontic Management of Bayonet Shaped Canals in Single and Multirooted Second Premolar – Case Series

Dr. Navdeep Jethi, ¹ Dr. Jyoti Beniwal, ² Dr. Falak Ashraf, ³ Dr. Vikram J. Nain, ⁴ Ish Singla ⁵

1. Dr. Navdeep Jethi

Senior Lecturer, Department of Conservative Dentistry and Endodontics, Daswani Dental Collage and Research Centre, Kota, Rajasthan.

2. Dr. Jyoti Beniwal

Prosthodontist, Dr. Harvansh Singh Judge Institute of Dental Sciences Hospital, Sector 25, South Campus, Panjab University, Chandigarh

3. Dr. Falak Ashraf

MDS Oral pathology, Daswani Dental Collage and Research Centre, Kota, Rajasthan

4. Dr. Vikram J. Nain

MDS (Prosthodontist), Shah Satnamji Speciality Hospitals, Sirsa

5. Dr. Ish Singla

Private Practitioner, Sirsa

Abstract

A good knowledge of root canal anatomy is necessary to deal with challenging cases in endodontic treatment. Often, two curvatures are seen in maxillary premolars in the same root canals, this two curvature root canal anatomy is referred as S shaped canals or Bayonet shaped root canals. Procedural errors such as ledges, fractured instruments, canal blockages, zip and elbow creations are common causes of failure in such cases. So a deep insight in the internal anatomy of the teeth before commencement of the treatment is necessary and routine IOPA can be used to assess the proper shape, form and morphology of the teeth, but sometimes an extra root may be not properly visible in them, so multiangled radiographs are essential for the diagnosis of such case. Here are two cases of endodontic treatment in Bayonet shaped root canals diagnosed, prepared and obturation with two different techniques.

Keywords: Bayonet shaped canals, S shaped canals, Vertucci classification, Maxillary second premolars, extra roots, Guttaflow.

INTRODUCTION

Root canal system of Maxillary second premolar demonstrates high variability and according to a study it was the only tooth to show all eight Vertucci's canal configurations.¹ According to Vertucci, maxillary second premolars shows maximum variations and bayonet shaped canal is one of such variations which is very difficult to negotiate.^{3, 4} The incidence of Vertucci's type II (two canal orifices end in one apical foramen,) and type IV (two canal orifices end in two separate apical foramina) is very common in case of second maxillary premolar.² Bayonet is a sword-like

stabbing blade which may be fixed to the muzzle of a rifle for use in hand-to-hand fighting. Bayonet shaped canals involve at least two curves, with the apical curve having maximum deviations in anatomy.⁷ Others teeth in which S-shaped canals are commonly found are maxillary lateral incisors, maxillary canines, maxillary first premolars, and mandibular molars.⁵

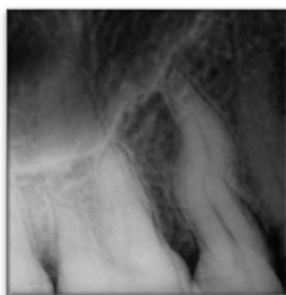S-shaped or bayonet shaped canals pose a big challenge while endodontic therapy.⁶ If they cross in mesiodistal direction, these double curvatures can be easily identified in radiographs but multi angled radiographs are needed when they traverse

in a buccolingual direction, and other chances to diagnose these canals is that when the initial file is removed out of the canal and multiple curvatures are seen in it.⁵For optimal biomechanical preparation of S-shaped canals, evaluation to the multiple concavities along the external surfaces of the root and three dimensional visualization of root canal anatomy is necessary because failure may leads to procedural errors.⁷This paper includes two case reports of bayonet shaped canals in Maxillary second premolars, diagnose, prepared and obturated with two different methods one with Guttaflow obturation in single root canal and other deals with Bayonet shaped canals in double rooted maxillary second premolar obturated with lateral condensation.

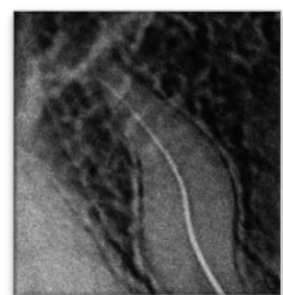
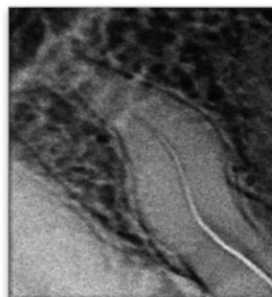
CASE REPORT 1: Aesthetic Obturation with Guttaflow

A 45 year old female patient was reported to department of conservative dentistry and endodontics in Daswani Dental College, Kota, with chief complaint of pain in posterior teeth region of upper jaw on chewing of food and sensitivity to hot, cold and sweet beverage. Pain was severe, boring, throbbing in nature which increases with hot stimulus. Tooth was tender on percussion and pulp was vital, confirmed with pulp tester. Radiographic findings include double curvature in root of the second premolar (15). After the informed consent the patient was anesthetised with L.A. and isolated properly with the help of rubber dam. Access was opened using round bur and refined using Endo Z bur. After flaring the canal orifice was opened and enlarged using S_x Protaper

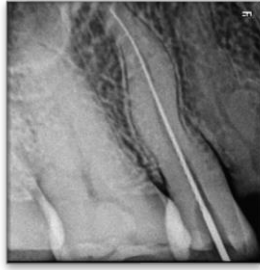file. The Canal was negotiated using K files (6, 8, and 10), an unrestricted approach to the first curve is necessary, and the shape of the removed files showed curvatures too. The working length was estimated from pre operative radiograph. In the middle third of the root first patency file (10 k file) was binding with dentinal walls. To lessen the degree of the curvature, anti curvature filing was done. Once the entire canal was negotiated, first, to facilitate biomechanical preparation of the apical curve, passive shaping of the coronal curve was done. Constant recapitulation with small files along with EDTA lubrication was used with double flaring technique for chemo mechanical preparation. Copious irrigation with saline and NaOCl was necessary to prevent blockage and ledging in the apical curve. Pre curving of the apical 3 mm of the file aids in maintaining the curvature of the canal. **Obturation** was done using Gutta flow, which is a silicon based obturation material, a combination of sealer and gutta percha. Initially a GP master cone was seated up to the apical third of the canal. Following the manufacturer's instructions, guttaflow was mixed in the capsule and the canal tip was placed onto the capsule, and the capsule into the dispensing gun. Small amount of guttaflow was dispensed over a pad to check the pink colour and ensure the proper mixing of the material before placing into the canal. The final obturation of the root canal was done using last apical file used to apply a small amount of the GuttaFlow into the root canal, master cone was seated, and backfilling was done with GuttaFlow.



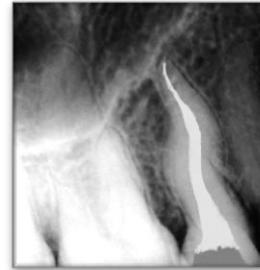
a) Pre Operative Radiograph



b) Canal Negotiation



c) Working Length



d) Obturation: Gutta Flow

Fig 1: Guttaflow obturation of the S shaped canals in Maxillary second premolar.

CASE REPORT 2: Bayonet Shaped Canals in Double Rooted Maxillary Second Premolar Obturated with Lateral Condensation

A 35 years old patient was reported to our department with a chief complaint of severe pain in second quadrant of maxillary jaw. Radiographic interpretation of a S shaped root canal anatomy was easy and double flare in the root was obvious in the IOPA. It was very difficult to say that this tooth had

any other root, when evaluated in preoperative IOPA. The patient was anesthetised with local anaesthesia and isolation in the oral cavity was done with a rubber dam. The access was prepared using no 2 and 4 round bur and while flaring of the tooth, the dentinal map revealed two canal orifices. The orifices were enlarged using GG drills and Sx protaper file was used for initial coronal flaring of both the canals.

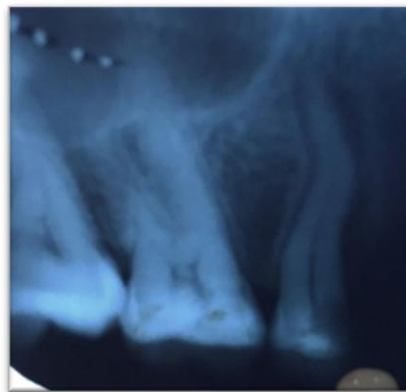

Fig 2: Radiographic evaluation of a Bayonet shaped canals in double rooted maxillary second premolar

Canals were negotiated with no 6, 8, and 10 files. The curvature was clearly visible on the files removed from each of the canals as they were bayonet shaped. But confusion was about the fact, that under which type the tooth morphology falls according to Vertucci's classification, the confirmation was done with changed angulations radiographs. The Digital radiographs revealed two separated roots in the tooth and both had double curvatures.

The working length was confirmed radiographically and copious irrigation with NaOCl and saline was admitted during chemomechanical preparation with NiTi 15K-35 K files in both the canals. After initial coronal flaring, the apical portion was prepared. Step back technique of canal preparation was used during the procedure, anti curvature filing was done to straighten the curvatures. Recapitulation was done along with irrigation. After proper preparation lateral condensation obturation technique was applied using GP cones and AH plus sealer.

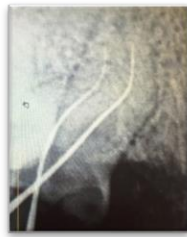
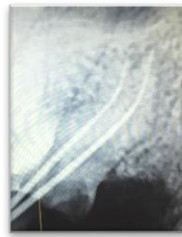
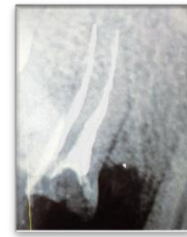


Fig 3: a) Working Length taken



b) Master cone RVG



c) Obturation Done

DISCUSSION

Due to double curvature, negotiation of S shaped canals is very difficult.^{1, 6} these are highly prone to chances of strip formation.⁵ Guttman suggested the preflaring of coronal 1/3rd of the canal to reduce the angle of the curvature.³ The access will make the approach to second curve much easier if we reduce the curvature.⁵ Preflaring was done with Sx file in both the cases and once it was done the apex was easily negotiable. For the preparation of the apical portion of the canals NiTi files were used. The apical enlargement was done up to 35 k as further enlargement can leads to iatrogenic error.³

Guttaflow is a silicone based sealer⁵ and endodontic treatment of the complex anatomy of the root canal can now be completed with the precise filling and sealing. Guttaflow has easy application technique along with its ability to expand, flow, and fill the 3D space in the canal makes it an excellent option for the permanent obturation of root canals.¹⁸ It is a mixture of Silicone with GP powder to form, a “two in one” cold filling system. It is supplied in unidose capsule & is injected after mixing or carried to canal on GP. After mixing GuttaFlow has a working time of 15 minutes and sets completely in 25 to 30 minutes. It is radiopaque in a final radiograph which should be taken after the completion of the root canal obturation.¹⁸

Literature is plentiful with the reports of extra canals in mandibular second premolars, but reports

about the incidence of extra roots in the maxillary premolars teeth are quite rare.⁹ Mandibular premolars have the most aberrant anatomy. A number of reports of root canal variations in these teeth have been reported in the literature.^{2,10} Vertucci reported 2.5% incidence of a second canal, in his series of studies conducted on extracted teeth.¹¹ 11.7% occurrence of two canals and 0.4% of three canals is reported by Zilich and Dawson.¹² Harty has reported 11% possibility of second canal. In most instances they have had one canal,^{13,14,15,16,17} In studies on extracted maxillary second premolars, it was found that 35.4% of them had two root canals at the apex. In Indians shows a higher incidence of type II configuration (33.6%) in the root canal morphology of the maxillary second premolar. The finding of additional type, namely type XIX (2-1-2-1), is rare. Highly variable anatomic structures in case of maxillary second premolars highly influence the clinical outcome of endodontic therapy.¹⁹

CONCLUSION

Successful endodontic therapy in S-shaped canals depend upon:

- Proper understanding of tooth morphology
- Correct radiographic technique and evaluation
- Choosing appropriate technique for cleaning and shaping of canals.
- Choosing a good obturation technique.

REFERENCES

1. F. Vertucci, A. Seelig, and R. Gillis, “Root canal morphology of the human maxillary second premolar,” *Oral Surgery Oral Medicine and Oral Pathology*, vol. 38, no. 3, pp. 456–464, 1974.
2. F. J. Vertucci, “Root canal anatomy of the human permanent teeth,” *Oral Surgery Oral Medicine and Oral Pathology*, vol. 58, no. 5, pp. 589–599, 1984.
3. Cohen. *Pathways of the pulp*. 9 Missouri: Mosby – Year book Inc; p. 152.
4. Ingle JI. *Root canal preparation*. In: *PDQ Endodontics*. BC Decker, Hamilton, Ontario, 2005; p. 129.
5. **Garg N, Garg A.** *Textbook of endodontics*. 2nd ed. New Delhi: Jaypee Brothers;2010.

6. Nasil Sakkir, Khaleel Ahamed Thaha, Mali G Nair, Sam Joseph, Christalin R. Management of Dilacerated and S-shaped Root Canals - An Endodontist's Challenge. *Journal of Clinical and Diagnostic Research* 8(6) · June 2014
7. Rashmi Bansal, Anuraag Gurtu, Nakul Mehrotra, Vidhi Agarwal, Anmol Mehrotra. S-shaped Canals. *Journal of Dental Sciences and Oral Rehabilitation, July-September 2016;7(3):152-154.*
8. Ricardo Machado, Antonis Chaniottis, Jorge Vera, Carlos Saucedo, Luiz Pascoal Vansan, and Emmanuel João ,Nogueira Leal Silva. S-Shaped Canals: A Series of Cases Performed by Four Specialists around the World. *Hindawi Publishing Corporation Case Reports in Dentistry, Volume 2014, Article ID 359438, 6 pages*
9. Prakash R, Nandini S, Ballal S, Kumar SN, Kandaswamy D. Two-rooted mandibular second premolars: Case report and survey. *Indian J Dent Res* 2008;19:70-3
10. Kerekes K, Tronstad L. Morphometric observations on root canals of human premolars. *J Endod* 1977;3:74-9.
11. Vertucci FJ. Root morphology of mandibular premolars. *J Am Dent Assoc* 1978;97:47-50.
12. Zilich R, Dowson J. Root canal morphology of mandibular first and second premolars. *Oral Surg Oral Med Oral Pathol* 1973;36:738-44.
13. ElDeeb ME. Three root canals in mandibular second premolars - literature review and case report. *J Endod* 1982;8:376-7.
14. Holtzman L. Root canal treatment of mandibular second premolar with four root canals: A case report. *Int Endod J* 1998;31:364-6.
15. Macri E, Zmener O. Five canals in a mandibular second premolar. *J Endod* 2000;26:304-5.
16. Trope M, Elfenbein L, Tronstad L. Mandibular premolars with more than one root canal in different race groups. *J Endod* 1986;12:343-5.
17. Wong M. Four root canals in a mandibular second premolar. *J Endod* 1991;17:125-6.
18. Robert Geller. GuttaFlow® for the Permanent Obturation of Root Canals: A Technique Review - *INSIDE DENTISTRY* Jan/Feb 2006 Volume 2, Issue 1
19. Udayakumar Jayasimha Raj, Sumitha Mylswamy. Root canal morphology of maxillary second premolars in an Indian population. *J Conserv Dent.* 2010 Jul-Sep; 13(3): 148–151. doi: 10.4103/0972-0707.71648.