

Optimizing Single Tooth Replacement: A Clinical and Radiological Evaluation of Basal Bi-cortical Screws Implants

Dr. Abhishek Pandey,¹ Dr. Amit Kumar Sharma,² Dr. Sunil Sharma³, Dr. Vikram Sharma⁴, Dr. Nisha Sharma⁵, Dr. Dhiral Vijayvargiya⁶

1. Dr. Abhishek Pandey

PG Resident, Department of Oral and Maxillofacial surgery, NIMS Dental College and Hospital, Jaipur, Rajasthan, India

2. Dr. Amit Kumar Sharma

Professor and Head, Department of Oral and Maxillofacial surgery, NIMS Dental College and Hospital, Jaipur, Rajasthan, India

3. Dr Sunil Sharma

Senior Professor, Department of Oral and Maxillofacial surgery, NIMS Dental College and Hospital, Jaipur, Rajasthan, India

4. Dr. Vikram Sharma

Professor, Department of Oral and Maxillofacial surgery, NIMS Dental College and Hospital, Jaipur, Rajasthan, India

5. Dr. Nisha Sharma

Assistant Professor, Department of Neuro-Anaesthesia, Mahatma Gandhi Medical College, Jaipur, Rajasthan, India

6. Dr. Dhiral Vijayvargiya

PG Resident, Department of Oral and Maxillofacial surgery, NIMS Dental College and Hospital, Jaipur, Rajasthan, India

CORRESPONDING AUTHOR

Dr. Amit Kumar Sharma

Professor and Head, Department of Oral and Maxillofacial Surgery, NIMS Dental College and Hospital, Jaipur, Rajasthan, India

Mobile – 9887347070

Email – bala.dr0359@gmail.com

Abstract

Objective: To evaluate the clinical and radiological outcomes of single tooth replacement using basal bicortical screws implants, focusing on primary stability, postoperative comfort, and patient satisfaction.

Methods: Twenty-five patients received BBS implants, with outcomes measured by insertion torque, periapical radiolucency, infection rates, implant mobility, and patient satisfaction using a Visual Analogue Scale and satisfaction surveys.

Results: A high rate of primary stability was observed with 64% of implants, low postoperative pain scores, and zero incidences of radiolucency, infection, or implant mobility. Variable patient satisfaction rates emphasized the importance of individualized care.

Conclusion: BBS implants are effective for single tooth replacement with excellent primary stability and minimal discomfort. However, patient satisfaction is varied, indicating a need for tailored patient care.

Categories: Dentistry

Keywords: Basal bicortical screws, post-extraction implant placement, Immediate functional loading, initial stability, clinical and radiological assessment

INTRODUCTION

Basal implantology has become a cornerstone in modern dental medicine, offering innovative solutions for patients with limited dental restoration options. This field has seen a significant shift, with a growing body of research dedicated to evaluating its effectiveness and longevity. The aim is to amalgamate these scholarly contributions to present an exhaustive overview of the progress and current status of basal implantology.

Contemporary dentistry strives to reinstate oral health to its natural state, addressing not just the functional and structural aspects but also considering aesthetic, phonetic, and psychosocial factors. The quest for knowledge, alongside advancements in diagnostic tools, implant designs, biomaterials, and surgical techniques, has greatly improved our capacity to manage intricate dental conditions¹.

The maxillary bone, especially in the dentate area, poses distinct challenges due to its varying density, which impacts implant-bone contact and the distribution of occlusal forces. Studies over the past twenty years have shown that factors such as implant length, bone quality, and individual patient factors like smoking and radiation exposure significantly influence implant survival rates. Choosing the right system is crucial for the biomechanical optimization of dental implants. Root form and basal implants, both essential to endosseous dental rehabilitation, differ in their insertion protocols, biomechanical load distribution, and clinical indications based on available bone anatomy. Root form implants are typically used when there is sufficient vertical bone height, while basal implants are beneficial in cases with compromised bone quality due to their engagement with the denser cortical bone.

Basal implantology is a distinct branch of implant dentistry, known for its wide-ranging indications and minimal constraints. The ‘dual-integration’ concept—initial and primary load transmission to the cortical bone followed by progressive osseointegration—highlights the body’s incredible ability to adapt and heal².

In the pursuit of dental restoration, achieving a stable and retentive smile is crucial for edentulous patients. The introduction of endosseous implants has transformed prosthodontic therapy, with both crestal and basal implants playing key roles in providing osseointegrated support for dentures. The differences between these implant types extend beyond their surgical insertion and biomechanical functions, affecting prosthodontic planning, execution, and postoperative care³.

The inherent strength and stability of the basal bone make it an excellent foundation for implant retention, offering a lasting solution for dental restoration. The evolution of basal implant systems, from the early work of Dr. Jean-Marc Julliet to the innovations by Dr. Gerard Scortecchi, has led to the development of BCS implants. These implants are sophisticated, minimally invasive, and designed for immediate interaction with the cortical bone, representing a significant advancement in the field⁴.

MATERIALS AND METHODS

Basal Bicortical Screw Implants: Revolutionizing Single Tooth Replacement

In the landscape of dental medicine, the advent of basal bicortical screw implants has marked a significant milestone, particularly in the realm of single tooth replacement. These implants stand out as a reliable and consistent option, offering a beacon of hope for patients who previously faced limited choices due to inadequate bone quality or quantity. The importance of meticulous clinical and radiological evaluation cannot be overstated, as it ensures that patients receive a treatment that is not only durable but also harmonizes with the intricate anatomy of the oral cavity. 25 BBSI system of basal implants were placed and evaluated clinically and radiologically for better outcome.

Clinical and Radiological Evaluation: A Pillar of Success

The evaluation process serves multiple critical functions. Firstly, it ascertains the suitability of basal bicortical screw implants, ensuring that the treatment outcome is effective and long-lasting. Secondly, it allows for the preservation of the

integrity of neighbouring teeth by negating the need for bridge supports. Thirdly, the health of the jawbone is of paramount importance; these implants leverage the jaw's basal cortical bone for stability and optimal load distribution. Radiological assessment is instrumental in confirming that the implants are positioned in the appropriate bone areas, fostering long-term bone preservation. Lastly, the aesthetic dimension is not overlooked; the evaluation aids in planning the position, alignment, and colour-matching of the implant, striving for an optimal aesthetic result that aligns with patient satisfaction.

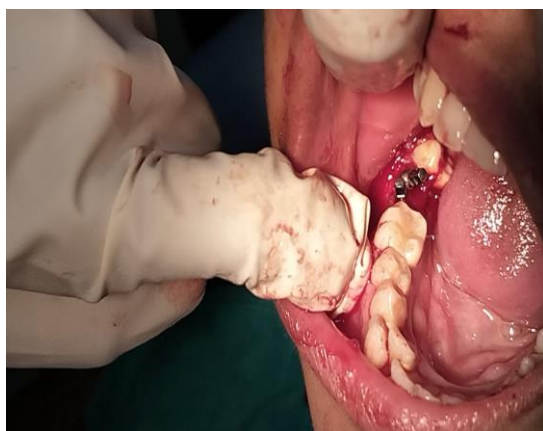Study Design: A Methodical Approach

The study's design was meticulously crafted to encompass a comprehensive evaluation of the patients requiring single tooth replacement. Detailed medical histories were collected, and informed consent was obtained, ensuring that participants

were fully aware of the study's purpose, risks, and benefits. The maxillofacial region was thoroughly assessed, focusing on bone quality, soft tissue health, and occlusion. Radiographic analysis, including pre- and post-operative imaging (CBCT, OPG, IOPA), provided a three-dimensional understanding of the implant sites and facilitated the evaluation of outcomes. Clinical photography documented the edentulous area and surrounding tissues, capturing standardized images from various angles.

Surgical Protocol: Precision and Care

The surgical intervention followed a protocol that emphasized precision and patient care. Pre-surgical planning was informed by the radiographic findings, and the surgery was conducted under strict sterilization standards. Post-operative analysis was integral to the study, monitoring implant stability and healing over time through follow-up radiographs and examinations. (fig)

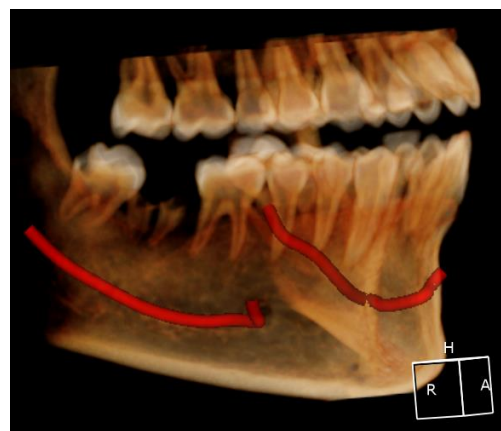
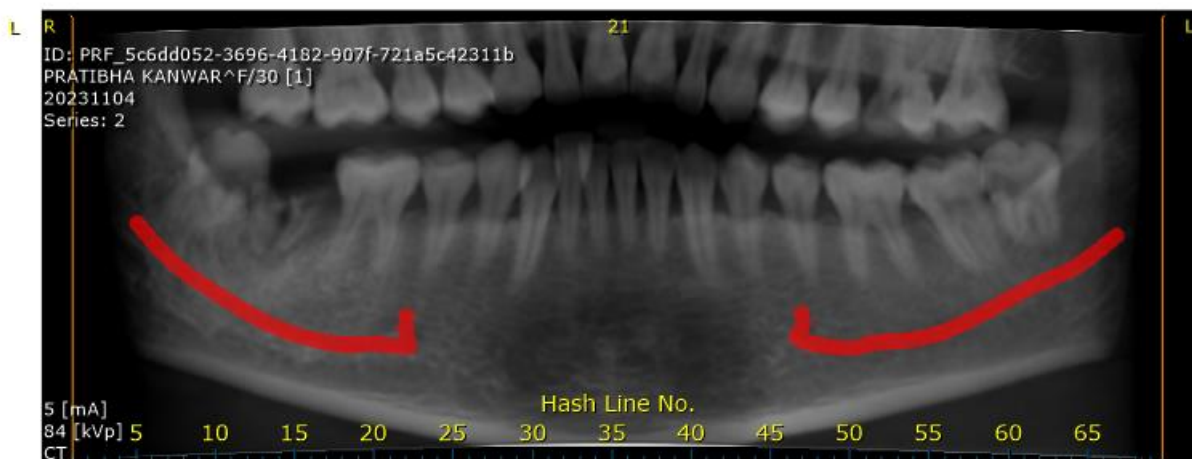
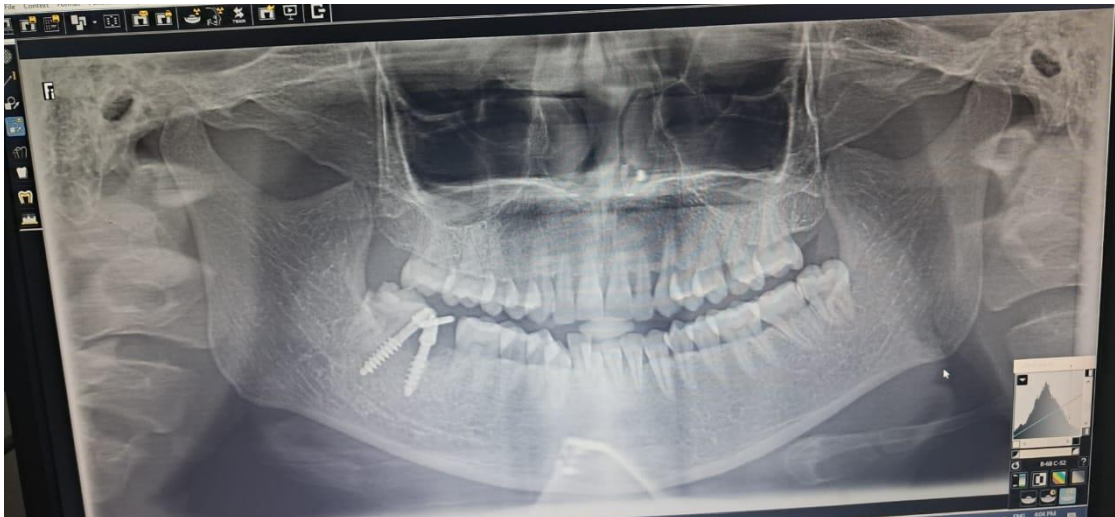



Figure: single tooth replacement with BBSI wrt 37.

Variables: Measuring Success

Several variables were considered to measure the success of the implant placement. The duration of the surgery, the patient's pain experience, the torque values for primary stability, the presence or absence of infection, and the evaluation of post-operative mobility were all meticulously recorded. Patient satisfaction levels were also gauged, providing a holistic view of the treatment's efficacy.

Assessment Methods: The data obtained was subjected to statistical analysis. The data recorded were transferred and tabulated to the computer - Windows Microsoft Excel (2007) - for the purpose of the data analysis. Statistical Package of Social Science (SPSS Version 20; IBM Chicago Inc., USA) was used for statistical analysis. The total data was subdivided and distributed meaningfully and presented as individual tables along with graphs. The significance level was fixed to be $p \leq 0.05$ for the analysis.

Depending upon the nature of the data, the statistical tests were chosen. Categorical data expressed in terms of frequency were analyzed for statistical significance using Chi square test. All continuous data were subjected to Kolmogorov Smirnov test for

normality. It was found that the data was normally distributed ($p > 0.05$) and hence parametric tests of significance were used. ANOVA was used to analyze the difference in the means of continuous variables. For all comparisons, p value of < 0.05 was considered to be statistically significant.

Results: The data obtained was subjected to statistical analysis. The data recorded were transferred and tabulated to the computer - Windows Microsoft Excel (2007) - for the purpose of the data analysis. Statistical Package of Social Science (SPSS Version 20; IBM Chicago Inc., USA) was used for statistical analysis. The total data was subdivided and distributed meaningfully and presented as individual tables along with graphs. The significance level was fixed to be $p \leq 0.05$ for the analysis. Depending upon the nature of the data, the statistical tests were chosen. Categorical data expressed in terms of frequency were analyzed for statistical significance using Chi square test. All continuous data were subjected to Kolmogorov Smirnov test for normality. It was found that the data was normally distributed ($p > 0.05$) and hence parametric tests of significance were used.

Table 7 : Comparative evaluation of the Insertion Torque

Based on the Insertion Torque						
Tooth Replaced	Counts	Low insertion torque/moderate primary stability (Less than 40)	High insertion torque/sufficient primary stability (40-50)	Very high insertion torque/excellent primary stability (Greater than 50)	Chi Square	p Value
11	3	1(50.0%)	1(6.2%)	1(14.3%)	21.168	0.733
12	3	1(50.0%)	2(12.5%)	0(0%)		
17	1	0(0%)	1(6.2%)	0(0%)		
21	1	0(0%)	1(6.2%)	0(0%)		
22	2	0(0%)	2(12.5%)	0(0%)		
23	1	0(0%)	0(0%)	1(14.3%)		
31	4	0(0%)	4(25.0%)	0(0%)		
32	1	0(0%)	1(6.2%)	0(0%)		
33	2	0(0%)	1(6.2%)	1(14.3%)		
41	1	0(0%)	0(0%)	1(14.3%)		
42	2	0(0%)	1(6.2%)	1(14.3%)		
43	2	0(0%)	1(6.2%)	1(14.3%)		
45	1	0(0%)	0(0%)	1(14.3%)		
47	1	0(0%)	1(6.2%)	0(0%)		

% Based on the Categorized Insertion Torque

Table 8: Comparative evaluation of the means of periapical radiolucency/infection and mobility and patient satisfaction

Based on the Periapical Radiolucency/ Infection and Mobility						%
Tooth Replaced	Counts	Periapical Radiolucency/ Infection	Mobility	Chi Square	p Value	
11	3	3(12.0%)	3(12.0%)	NA	NA	
12	3	3(12.0%)	3(12.0%)			
17	1	1(4.0%)	1(4.0%)			
21	1	1(4.0%)	1(4.0%)			
22	2	2(8.0%)	2(8.0%)			
23	1	1(4.0%)	1(4.0%)			
31	4	4(16.0%)	4(16.0%)			
32	1	1(4.0%)	1(4.0%)			
33	2	2(8.0%)	2(8.0%)			
41	1	1(4.0%)	1(4.0%)			
42	2	2(8.0%)	2(8.0%)			
43	2	2(8.0%)	2(8.0%)			
45	1	1(4.0%)	1(4.0%)			
47	1	1(4.0%)	1(4.0%)			

Based on the Categorized Periapical Radiolucency / Infection and Mobility ; NA - Not Applicable

Based on the Patient Satisfaction						
Tooth Replaced	Counts	Very dissatisfied	Dissatisfied	Satisfied	Chi Square	p Value
11	3	0(0.0%)	3(23.1%)	0(0.0%)	29.879	.273
12	3	1(33.3%)	1(7.7%)	1(11.1%)		
17	1	1(33.3%)	0(0.0%)	0(0.0%)		
21	1	0(0.0%)	0(0.0%)	1(11.1%)		
22	2	1(33.3%)	0(0.0%)	1(11.1%)		
23	1	0(0.0%)	1(7.7%)	0(0.0%)		
31	4	0(0.0%)	3(23.1%)	1(11.1%)		
32	1	0(0.0%)	1(7.7%)	0(0.0%)		
33	2	0(0.0%)	0(0.0%)	2(22.2%)		
41	1	0(0.0%)	1(7.7%)	0(0.0%)		
42	2	0(0.0%)	1(7.7%)	1(11.1%)		
43	2	0(0.0%)	2(15.4%)	0(0.0%)		
45	1	0(0.0%)	0(0.0%)	1(11.1%)		
47	1	0(0.0%)	0(0.0%)	1(11.1%)		

% Based on the Categorized Patient Satisfaction

Table 9 : Comparative evaluation of the means of the Duration Of surgery & Insertion Torque

Based on the Duration Of surgery (mins)										
Parameters	Tooth Replaced	Counts	Mean	Std. Deviation	Std. Error of Mean	Minimum	Maximum	Median	Range	ANOVA (p Value)
Duration Of surgery	11	3	45	13.22876	7.637626	30	55	50	25	.379
	12	3	46.66667	11.54701	6.666667	40	60	40	20	
	17	1	55	-	-	55	55	55	0	
	21	1	50	-	-	50	50	50	0	
	22	2	35	7.071068	5	30	40	35	10	
	23	1	50	-	-	50	50	50	0	
	31	4	41.25	4.787136	2.393568	35	45	42.5	10	
	32	1	45	-	-	45	45	45	0	
	33	2	37.5	10.6066	7.5	30	45	37.5	15	
	41	1	35	-	-	35	35	35	0	
	42	2	32.5	3.535534	2.5	30	35	32.5	5	
	43	2	40	0	0	40	40	40	0	
	45	1	55	-	-	55	55	55	0	
	47	1	60	-	-	60	60	60	0	

Based on the Insertion Torque wrench values (Ncm)										
Parameters	Tooth Replaced	Counts	Mean	Std. Deviation	Std. Error of Mean	Minimum	Maximum	Median	Range	ANOVA (p Value)
Insertion Torque	11	3	45	15	8.660254	30	60	45	30	.988
	12	3	45	8.660254	5	35	50	50	15	
	17	1	40	-	-	40	40	40	0	
	21	1	45	-	-	45	45	45	0	
	22	2	45	7.071068	5	40	50	45	10	
	23	1	55	-	-	55	55	55	0	
	31	4	48.75	4.787136	2.393568	45	55	47.5	10	
	32	1	50	-	-	50	50	50	0	
	33	2	47.5	10.6066	7.5	40	55	47.5	15	
	41	1	55	-	-	55	55	55	0	
	42	2	50	14.14214	10	40	60	50	20	
	43	2	52.5	10.6066	7.5	45	60	52.5	15	
	45	1	60	-	-	60	60	60	0	
	47	1	45	-	-	45	45	45	0	

Insertion Torque Stability

The success of a dental implant is often predicted by its primary stability, which is measured by the insertion torque. In our study, we found that a majority of the implants (64%) achieved high insertion torque values between 40-50 Ncm. This suggests that these implants had sufficient primary stability, which is a positive indicator for successful osseointegration. Furthermore, 28% of the implants demonstrated very high insertion torque values over 50 Ncm, indicative of excellent primary stability. Only a small fraction of implants (8%) were associated with lower insertion torque values under 40 Ncm, signaling moderate primary stability. This distribution indicates that most implants placed achieved a level of torque considered conducive to successful osseointegration.

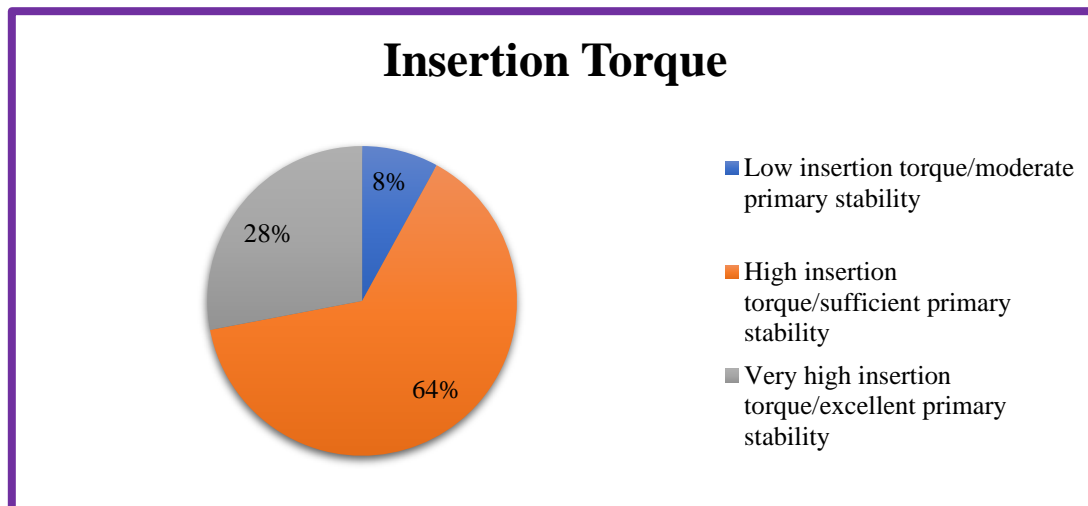
Pain Assessment

Postoperative pain was measured using the Visual Analogue Scale (VAS). The results were quite promising, with the vast majority of patients (88%)

experiencing only mild pain (VAS score 1-3). A smaller subset of patients (12%) reported no pain post-surgery. These findings suggest that the implant placement procedure associated with basal bicortical screws is generally well tolerated by patients, contributing to a more positive overall experience.

Periapical Radiolucency/Infection and Implant Mobility

Critical indicators of implant success include the absence of signs of infection and implant mobility. Our study showed an encouraging outcome in this regard, with none of the patients exhibiting periapical radiolucency or signs of infection in follow-up radiographs done at period of 1st and 3rd month. Additionally, there was no reported postoperative mobility in any of the implants. This suggests a high level of stability and successful integration of the implants within the oral environment, which is crucial for long-term success and patient comfort.



Patient Satisfaction

Patient satisfaction is a multifaceted metric that reflects the success of dental treatments. In our assessment, while 36% of patients expressed satisfaction with their implants, a significant number (64%) expressed some level of dissatisfaction. This emphasizes the importance of setting realistic expectations and the need for tailored treatment plans to improve patient satisfaction rates in dental implantology. It's a reminder that while clinical success is important, the patient's perception of success is equally vital.

Surgical Duration and Efficiency

The time efficiency of the surgery was evaluated, and the mean duration of the dental implant surgeries was 43.2 minutes. Surgery times showed some variability, with a standard deviation of 9.34 minutes. The minimum and maximum durations of surgery were 30 minutes and 60 minutes, respectively. This data provides valuable insights into the efficiency of the surgical procedure and can be used to further optimize the process for better patient experience and outcomes.

This study provides valuable insights into the clinical and radiological outcomes of single tooth replacement with basal bicortical screws implants. The findings underscore the importance of several factors in the success of dental implants, including insertion torque stability, pain management, infection control, implant mobility, patient satisfaction, and surgical efficiency. Our study demonstrated that the surgical procedure for single tooth replacement using basal bicortical screws is relatively consistent in terms of surgical duration

and insertion torque, regardless of the tooth replaced. Additionally, most patients experience only mild pain postoperatively, suggesting effective pain management protocols. The clinical implications of these results indicate that surgeons can expect predictable surgical times and torque values when placing basal bicortical screws for single tooth implants, contributing to efficient surgical planning and positive patient outcomes. Future research should aim to build on these findings to further improve outcomes and patient satisfaction in dental implantology.

DISCUSSION

Implants are frequently used as a treatment choice for partially or fully toothless patients. **Branemark**¹ was the first to describe the use of dental implants for prosthetic rehabilitation, reporting an 81% survival rate for maxillary arches and 100% for mandibular arches. The success of implants is closely tied to the osseointegration process, which has seen improvements in recent years due to enhanced implant design and surface topography. **Dr. Jean-Marc Julliet** developed the initial single-piece implant, later improved by **Dr. Gerard Scortecchi**⁹ Furthermore, **Dr. Stefan Ihde** adapted lateral basal implants into screwable bi-cortical ones.

Yadav et al.⁴ defined basal implantology—also referred to as bi-cortical implantology—as a contemporary system that utilizes cortical bone areas following orthopaedic surgery principles, leading to what can be termed "orthopaedic implants." According to **Nair C Bharathi S**⁵, two types of basal screws—basal osseointegrated [BOI]

and Basal Cortical Screw [BCS], designed specifically for utilizing cortical bone—provide good primary stability. A special type involves using 12mm thread diameter screwable implants placed into freshly extracted tooth sockets. Dental implants are often used to replace missing teeth in order to preserve the alveolar bone. Endosteal implants according to **Zarb G Schmitt A, (1996)**³⁰ can help maintain bone width and height as long as they remain healthy.

Basal bone, which forms the dental skeletal structure, is resistant to resorption and serves as a stress-bearing portion of the jaws due to its muscle attachments.

The design of basal bicortical screw implants allows them to anchor in the 2nd cortical bone, providing excellent primary stability along the vertical surface without requiring corticalization. Studies by **Dos Santos, (2011)**²¹ and **Seeman and Delmas (2006)**³² have shown that implant stability is influenced by factors such as bone quality at the site, implant geometry, drilling sequence, and bone density - which primarily determines strength and stability. A retrospective study by **Narang et al, (2016)**²² on immediately loaded single-piece implants demonstrated a high cumulative survival rate of 95.7% over an average observation period of 18.93±8.41 months. This success highlights how anchoring basal implants in the 2nd cortical bone through Osseo fixation allows for functional loading in edentulous jaws compared to traditional crestal implants.

Visual Analogue Scales have been used widely and effectively in psychological medicine as clinical and research tools. Although they have been used largely to measure subjective experiences, they have also been used for behavioural measurement. Most VAS described in the literature are designed for self-assessment; however, several studies have also used them for observer rating, and have reported significant levels of inter-rater reliability when used in this way, **Heather M. McCormack, (1988)**⁵⁴.

A retrospective literature review study by **Greenstein G(2017) et al**⁵⁵. on the effects of minimum and maximum forces that can be used to successfully place implants. The minimum torque that can be employed to attain primary stability is undefined. Forces ≥ 30 Ncm are routinely used to

place implants into healed ridges and fresh extraction sockets prior to immediate loading of implants. Increased insertion torque (≥ 50 Ncm) reduces micromotion and does not appear to damage bone. In general, the healing process after implant insertion provides a degree of biologic stability that is similar whether implants are placed with high or low initial insertion torque. Primary stability is desirable when placing implants, but the absence of micromotion is what facilitates predictable implant osseointegration. Increased insertion torque helps achieve primary stability by reducing implant micromotion.

After reviewing several studies **Anita Gala Doshi (2023)**⁴⁴ et al. concluded Basal implants allow for immediate loading and osseofixation. The immediate loading of basal implants reduces the treatment time and cost for patients and allows for immediate function. The immediate loading also reduces the risk of implant failure and bone loss. Immediate loading has several advantages over delayed loading, which is the traditional approach where a crown or bridge is placed on the implant several months after placement to allow for osseointegration. One of the main advantages of immediate loading is that it reduces the treatment time for the patient. Patients can receive their new teeth on the same day as implant placement, which is a significant improvement over traditional implants that require several months of healing before the final restoration can be placed.

A recent study by **H. Gosai et al. (2021)**⁴² has provided evidence supporting the efficacy of these implants. The research indicates that after the placement of basal bicortical screw implants, there was an absence of peri-implant radiolucency and mobility seen during the time of final prosthesis delivery and upon follow up period, which are key indicators of implant stability and osseointegration. Single tooth replacement with basal bicortical screw implants, patient satisfaction is particularly important. A study by **Fadia Awadalkreem et al(2020)**⁵⁶ found that patients' general satisfaction with basal implants was very high. The satisfaction covered various aspects such as comfort, mastication, speech, and aesthetics, all of which significantly improved with the new basal implants. Even in cases where patients had

complaints, they still expressed high satisfaction and would choose the same treatment modality again.

In our present study of placement of 25 BCS implants immediately in freshly extracted teeth socket and with immediate loading within 72 hours of implant placement shows a synthesis of the clinical and radiological data acquired through meticulous research. The statistical analysis, leveraging the robust capabilities of SPSS Version 20, has provided a comprehensive understanding of the efficacy and outcomes associated with basal bicortical screws implants. According study done by **H. Gosai et al. (2021)**⁴² it is stated that there is a limited role for variously treated implant surfaces for immediate loading protocol, as in 72 h, the bone neither heals nor integrates with the implant devices. The basal implants and internal fixation devices of traumatology are considered “osseofixated” in stable cortical bone with almost no metabolism. Secondary osseointegration would occur later into the endosseous parts of the implants contacting cancellous bone.

Primary Stability and Insertion Torque: Our study delved into the critical aspect of primary stability of dental implants, a cornerstone for successful osseointegration. We measured the insertion torque to assess this stability. A promising 64% of the implants showcased high insertion torque values, a clear indication of adequate primary stability. This is a strong testament to the precision and dependability of the surgical techniques we employed. Moreover, 28% of the implants displayed very high insertion torque, signifying exceptional primary stability and hinting at a positive prognosis for enduring success. A small fraction (8%) fell into the moderate primary stability category, which is still within the clinically acceptable limits.

When we compared the insertion torque values across various teeth replacements, we found a uniform distribution of these values. Interestingly, there was no significant difference in the mean values (ANOVA p-value: .968). The range of these values, from 0 to 30 Ncm, mirrors the individual variability in the surgical procedure and patient anatomy. The standard deviation and standard error values suggest that while there is some variability in insertion torque, it falls within an acceptable range for clinical practice. These findings underscore the

consistency in achieving the desired torque values, a critical factor for the immediate stability and long-term success of dental implants. The data supports the conclusion that the type of tooth replaced does not significantly impact the ability to achieve optimal insertion torque during implant surgery.

Pain Perception and Patient Experience: We also evaluated the postoperative experience using the Visual Analogue Scale (VAS). The results were encouraging, with the majority of patients (88%) reporting only mild pain. This underscores the effectiveness of our pain management protocols and aligns with our overarching goal of patient-centred care, where minimizing discomfort is paramount. The mean score of 1.72 is indicative of successful pain management strategies. The low standard deviation and error of the mean suggest that the experience of pain is consistently managed across the patient population. Our comparative evaluation of pain levels using the VAS scale indicates that most patients experience low to moderate pain following dental implant surgery, with mean scores ranging from 0 to 3. The lack of significant variation in pain scores across different teeth (ANOVA p-value: .084) suggests that the type of tooth replaced does not significantly affect the patient’s postoperative pain experience. However, the p-value is close to the threshold for significance, indicating that further research with a larger sample size might be necessary to conclusively determine if there are differences in pain perception based on the tooth replaced.

Patient Satisfaction: Patient satisfaction is a complex measure influenced by aesthetic results, functional recovery, and overall patient experience. Our study found that while 52% of patients were satisfied, a significant 36% showed some degree of dissatisfaction, and 12% were highly dissatisfied. These numbers emphasize the need for ongoing enhancements in patient communication, managing realistic expectations, and personalized care plans. Our research investigated patient satisfaction across different dental implants, uncovering a range of satisfaction levels. Despite these variations, a Chi Square statistical analysis did not show significant differences among the replaced teeth ($p = .273$). This indicates that factors not covered in this study might affect patient perceptions. Future studies should take

into account individual patient characteristics, surgical methods, and post-operative care to fully comprehend the factors influencing satisfaction. In conclusion, our results highlight the intricacy of patient satisfaction and the necessity for tailored strategies in dental implantology. This underscores the importance of a holistic approach to patient care, where every aspect of the patient's journey is considered and addressed.

Infection Control and Implant Mobility: In 2016, **S. Ihde and A Ihde**⁹ proposed the concept of “supporting polygon” to determine the position of occlusal contacts within or outside of polygon drawn up by the load transmitting part of the implants in the second or third corticals. The aim of the treatment for work on strategic basal implants should be: • A bilateral equal and symmetrical occlusion • A bilateral equal and symmetrical mastication, with contact on first, second premolar, and the mesial half of first molar • A symmetrical function of the muscles, especially tongue Identical angle functional masticatory de planus (AFMP) angles on both the sides. In a case report, **Stefan Ihde and Antonina Ihde**²¹ evaluated the bone reaction to the polished surface and sandblasted surface in a case and evaluated it over a period of 20 years. They stated that polished vertical implant surfaces on lateral basal implants and a thin diameter at the point of mucosal penetration provide a sustainable environment for a stable (unaltered) bone level even after 20 years. Our study found that there were no instances of infection or mobility post-operation in all the cases we analyzed during the time of placement and at the time of follow up at 1st and 3rd month using OPG scans . This is a positive sign for the effectiveness of both the design of the implants and the surgical techniques used. These favourable outcomes underscore the biocompatibility of the materials used in the implants. They also suggest a high level of skill in their placement, reinforcing the reliability of these implants for single tooth replacement.

Surgical Efficiency: We analyzed the duration of dental implant surgeries across various types of teeth in this study. The results show that the average time taken is relatively consistent, with no significant differences observed (ANOVA p-value: .379). The range of surgery times, from 0 to 25 minutes, reflects

the complexities and challenges of individual cases. The standard deviation and standard error values indicate a moderate dispersion around the mean. This suggests that while some surgeries may take longer or shorter than the average, most fall within a predictable timeframe. This consistency in surgical duration is crucial for efficient scheduling and managing patient expectations. It highlights the standardized nature of these procedures in oral and maxillofacial surgery. Our findings suggest that the duration of surgery is not significantly affected by the type of tooth being replaced. This indicates that other factors may play a more critical role in determining the length of the procedure.

Statistical Significance: The study adhered to a significance threshold of $p \leq 0.05$, ensuring a robust analysis of the data. While most comparisons yielded a non-significant p-value, indicating no substantial differences in primary stability and patient-related outcomes, attention should be directed toward the borderline significances that could warrant further exploration.

Oleg et al.⁶⁸ and **Lazarov**⁶⁹ also showed BECES® implants being the maximally used basal implant type in their studies 89.6% and 87.1%, respectively. Basal bicortical screws implants have emerged as a reliable and effective option for single tooth replacement. The clinical and radiological evaluations conducted in the thesis have substantiated their role in achieving satisfactory primary stability and patient outcomes. As the field of dental implantology continues to evolve, the findings of this study will serve as a valuable reference point for both current practitioners and future research endeavours. This underscores the importance of continuous learning and adaptation in the field of dental implantology. It also highlights the potential of basal bicortical screws implants in improving patient outcomes and satisfaction. Drawing from the knowledge gained in this study, it becomes clear that subsequent research needs to dig deeper into the elements that lead to patient dissatisfaction. It's crucial to comprehend the fundamental sources of discomfort, whether they're rooted in physical or mental aspects. This understanding will play a pivotal role in improving patient outcomes.

Moreover, the exploration of progress in the field of implant design and surgical methodologies could provide avenues to further reduce pain and enhance the reliability of successful implant procedures. Every patient's journey is unique, and their comfort and satisfaction are paramount. Therefore, understanding their experiences, fears, and expectations can help us tailor treatments that not only address their clinical needs but also their holistic well-being.

CONCLUSION

The primary stability of dental implants is a crucial aspect that can significantly impact the long-term success of the restoration. The research conducted on basal bicortical screws implants has shed light on their ability to provide high insertion torque values, indicating robust primary stability⁵⁷.

This characteristic is attributed to the design of these implants, which anchor into the basal cortical bones known for their reduced susceptibility to resorption and infection. The unique ability of basal bicortical screws implants to offer strong primary stability is particularly advantageous in cases where the surrounding bone may not be able to adequately support traditional implants⁶².

Efficient pain management and a well-tolerated surgical technique are critical components of a successful dental implant procedure. The study provides significant insights into the effectiveness of pain management during the insertion of basal bicortical screws implants. The majority of patients reported minimal discomfort, signifying that the associated surgical technique is well-tolerated⁵⁸.

This aspect is not only essential for patient comfort but also for the overall success and acceptance of the implant procedure. The absence of post-surgical complications such as infection or implant mobility indicates the stability and integrity provided by basal bicortical screws implants within the oral environment. However, the variability in patient satisfaction underlines the importance of implementing a personalized care approach, acknowledging that individual experiences and preferences play a significant role in shaping the overall perception of the implant treatment⁵⁹.

Consistent operative times reflect a standard and efficient surgical method, which can streamline clinical workflow and improve patient convenience.

This efficiency is a valuable aspect of basal bicortical screws implants, contributing to a positive overall experience for both patients and dental practitioners⁶⁰.

SUMMARY

While acknowledging the limitations of a small and homogeneous sample size, the study also emphasizes the potential for future research to expand the findings to diverse patient populations and compare them with other implant systems⁶¹. The pursuit of further research is essential in establishing the broader applicability and efficacy of basal bicortical screws implants as a reliable alternative for single tooth replacement. Summarising the findings of this study provide substantial support for considering basal bicortical screws implants as a viable option for single tooth replacement, especially in scenarios where traditional implants may not be suitable due to limitations in bone quality or quantity⁶³.

However, comprehensive research endeavours are required to validate their long-term efficacy and comparative benefits and to solidify their position among the spectrum of available implant systems. As the field of implant dentistry continues to evolve, a deeper understanding of basal bicortical screws implants and their clinical outcomes will contribute to expanding treatment options for diverse patient populations. Consistent operation times reflect standard and efficient surgical methods that enhance workflow efficiency. Techniques specific to Basal Bicortical Screws contribute to a positive overall experience for both practitioners and recipients alike. While acknowledging the limitations of a small, homogenous sample size, it is essential to emphasize potential future expansion into diverse patient populations when comparing them with other systems in order to fully understand their efficacy as viable alternatives for single tooth replacement.

Funding

No funding, grants or other support was received.

Data availability

The data presented in this study are available on request from the corresponding author. The data are not publicly available due to privacy regulation.

Conflict of interest

The authors declare no conflict of interest.

Institutional review board statement

Ethical approval was waived by local ethical committee of Nims University Rajasthan. In view of

nature of the study and all procedures being performed were part of routine care.

Informed consent statement

Patient consent was taken.

BIBLIOGRAPHY

1. Zarb GA. Introduction to osseointegration in clinical dentistry. *J Prosthet Dent* 1983; 49:824
2. Grossmann Y, Sadan A. The prosthodontic concept of crown-to-root ratio: A review of the literature. *J Prosthet Dent* 2005; 93:559–562.
3. Misch CE: Bone density effect on treatment planning, surgical approach and progressive loading, *Int J Oral Implant* 6:23-31, 1990.
4. An Alternative to Conventional Dental Implants: Basal Implants Yadav RS, Sangur R, Mahajan T, Rajanikant AV, Singh N, Singh R Rama Univ *J Dent Sci* 2015 June;2(2):22-28
5. Nair C, Bharathi S, Jawade R, Jain M. Basal implants-a panacea for atrophic ridges. *Journal of dental sciences & oral rehabilitation*. 2013 Mar;1-4
6. Ihde S. Restoration of the atrophied mandible using basal osseointegrated implants and fixed prosthetic superstructures. *Implant Dent* 2001;10:41– 45.
7. Becker W, Goldstein M, Becker BE, Sennerby L. Minimally invasive flapless implant surgery: a prospective multicenter study. *Clinical implant dentistry and related research*. 2005 Jun;7: s 21-7
8. Rocci A, Martignoni M, Gottlow J. Immediate loading in the maxilla using flapless surgery, implants placed in predetermined positions, and prefabricated provisional restorations: a retrospective 3- year clinical study. *Clinical implant dentistry and related research*. 2003 Mar;5:29-36.
9. Zarb G Schmitt A: Edentulous predicament. I. A prospective study of the effectiveness of implant supported fixed prostheses, *J Am Dent Assoc* 127:59- 72,1996
10. Lekholm U, Zarb GA: Patient selection and preparation. In Branemark P-I, Zarb GA, Albrektsson T, editors: *Tissue integrated prostheses: osseointegration in clinical dentistry*, Chicago, 1985, Quintessence
11. H Gosai., S. Anchlia, Kiran V. Patel, U. Bhatt, P. Chaudhari, and N. Garg. “Versatility of Basal Cortical Screw Implants with Immediate Functional Loading.” *Journal of Maxillofacial and Oral Surgery* 21 (2021): 824–32. <https://doi.org/10.1007/s12663-021-01638-6>
12. Basal Implants: A Narrative Review Anita Gala Doshi et al. ; *IOSR Journal of Dental and Medical Sciences (IOSR-JDMS)* e-ISSN: 2279-0853, p-ISSN: 2279-0861. Volume 22, Issue 6 Ser.13 (June. 2023), PP 54-65 www.iosrjournals.org
13. Heather M. McCormack, David J. de L. Horne and Simon Sheather (1988). Clinical applications of visual analogue scales: a critical review. *Psychological Medicine*, 18, pp 10071019 doi:10.1017/S0033291700009934
14. Greenstein G, Cavallaro J. Implant Insertion Torque: Its Role in Achieving Primary Stability of Restorable Dental Implants. *Compendium of Continuing Education in Dentistry (Jamesburg, N.J. : 1995)*. 2017 Feb;38(2):88-95; quiz 96. PMID: 28156122.
15. Fadia Awadalkreem et al. The Influence of Immediately Loaded Basal Implant Treatment on Patient Satisfaction *Hindawi International Journal of Dentistry* Volume 2020, Article ID 6590202, 10 pages <https://doi.org/10.1155/2020/6590202>
16. McCormack HM, de L. Horne DJ, Sheather S. Clinical applications of visual analogue scales: a critical review. *Psychological Medicine*. 1988;18(4):1007-1019. doi:10.1017/S0033291700009934
17. Vajdi Mitra G, Agrawal N, Shukla N, Aishwarya K, C C P, Raj A. An Evaluation of the Efficacy and Acceptability of Basal Implants in Traumatically Deficient Ridges of the Maxilla and the Mandible. *Cureus*. 2023 Aug 13;15(8):e43443. doi: 10.7759/cureus.43443. PMID: 37711942; PMCID: PMC10498012.
18. Anuradha M, Babaji HV, Hiremath NV, Usha VA, Kumar A, Nandkeoliar T, Verma S. Assessment of basal implants in compromised ridges. *J Family Med Prim Care*. 2020 Apr 30;9(4):2067-2070. doi: 10.4103/jfmpe.jfmpe_1149_19. PMID: 32670967; PMCID: PMC7346953
19. Efficacy of Single Piece Basal Implant in Dentoalveolar Rehabilitation Dr. Ashish Chaturvedi, 1 Dr. Vinay Kumar, 2 Dr. Sankalp Mittal, 3 Dr. Sunil Jakhar, 4 Dr. Mohit Agrawal, 5 Dr. Sonal Priya Bhansali 6 ://National Research Denticon, Vol-11 Issue No. 1, Jul. - Dec. 2022
20. Wang X, Kattan MW. Cohort Studies: Design, Analysis, and Reporting. *Chest*. 2020

Jul;158(1S):S72-S78. doi:

10.1016/j.chest.2020.03.014. PMID: 32658655.

21. <https://www.semanticscholar.org/paper/afede67456c76af5fad3ca92f3f3e3357206b16e>
22. Oleg D, Alexander L, Konstantinović VS, Olga S, Damir S, Biljana M. Immediate-functional loading concept with one-piece implants (Beces/Beces N/Kos/Boi) in the mandible and maxilla- a multi-center retrospective clinical study. J Evol Med Dent Sci. 2019;8(5):306–15. doi: 10.14260/jemds/2019/67. [[CrossRef](#)] [[Google Scholar](#)]
23. Lazarov A. Immediate functional loading: results for the concept of the strategic implant® Ann Maxillofac Surg. 2019;9(1):78–88. doi: 10.4103/ams.ams_250_18. [[PMC free article](#)] [[PubMed](#)] [[CrossRef](#)] [[Google Scholar](#)]