



**ISSN 2395-6844**

# **National Research Denticon**

**An Official Publication of  
Rajasthan University of Health Sciences, Jaipur**

**Issue: Vol. 13, No.3**

**Jul to Sep 2024**

# INDEX

<b>List of Articles</b>		<b>Pages No.</b>
Evaluation of Relationship Between the White Blood Cell Count and the Gingival Health of Children with Beta Thalassemia Major - An Observational Study	<b>Dr. Anusha Dixit</b>	<b>1 - 6</b>
Evaluation of Postoperative Pain after the Use of 5.25% Sodium Hypochlorite Gel, Solution at Room Temperature & Heated Solution Form at 50°C as Intracanal Irrigant: In Vivo Study	<b>Dr. Irshad Ali</b>	<b>7 - 12</b>
Comparative Evaluation of Behavioral Efficacy of 4% Articaine With 24 Gauge Needle in Buccal Nerve Block Compared to 2% Lignocaine With 20 Gauge Needle in Inferior Alveolar Nerve Block in Children With Dento - Alveolar Abscess	<b>Dr. Jyoti Sharma</b>	<b>13 - 22</b>
Comparative Evaluation Of Dentinal Crack Formation After Using Protaper Universal, Protaper Gold, Hyflex EDM, And Neoendo Flex Rotary File Systems: An In Vitro Study	<b>Dr. Mintu Maria Joseph</b>	<b>23 - 30</b>
Dentin Bonding Unveiled: A Look at the Past, Present and Future Innovations	<b>Dr. Tarunpreet Kaur Dhami</b>	<b>31 - 37</b>
Comparison of Marginal and Internal Fit of Metal Copings Fabricated by Cad/Cam Milling, Cad/Cam Wax and Conventional Lost Wax Technique	<b>Dr. Vineeta Tailor</b>	<b>38 - 46</b>
Management of Introral Low-Flow Vascular Malformations By Intralesional Injection of Bleomycin In Paediatric Patient:  A Case Report	<b>Dr. Mansi Lalwani</b>	<b>47 - 50</b>

# Evaluation of Relationship Between the White Blood Cell Count and the Gingival Health of Children with Beta Thalassemia Major - An Observational Study

Dr. Anusha Dixit,<sup>1</sup> Dr. Ashish Saxena,<sup>2</sup> Dr. Vishal Khandelwal,<sup>3</sup> Dr. Neha Verma,<sup>4</sup>  
Dr. Anuradha Agrawal,<sup>5</sup> Dr. Priya Gupta<sup>6</sup>

**1. Dr. Anusha Dixit**

Postgraduate Student, MDS 2<sup>nd</sup> year, Department of Paediatric and Preventive dentistry, Government college of Dentistry, Indore, Madhya pradesh, India

**2. Dr. Ashish Saxena**

MDS, Professor and Head, Department of Paediatric and Preventive Dentistry, Government College of Dentistry, Indore, Madhya pradesh, India

**3. Dr. Vishal Khandelwal**

MDS, Assistant Professor, Department of Paediatric and Preventive Dentistry, Government College of Dentistry, Indore, Madhya pradesh, India

**4. Dr. Neha Verma, MDS**

Lecturer, Department of Prosthodontics, Crown and Bridge and Implantology, Government College of Dentistry, Indore, Madhya pradesh, India

**5. Dr. Anuradha Agrawal**

MDS, Associate Professor Department of Paediatric and Preventive Dentistry, Government College of Dentistry, Indore, Madhya pradesh, India

**6. Dr. Priya Gupta**

Student, MDS 2<sup>nd</sup> Year, Department of Paediatric and Preventive Dentistry, Government College of Dentistry, Indore, Madhya pradesh, India

## CORRESPONDING AUTHOR

**Dr. Anusha Dixit**

Room No.18, 1<sup>st</sup> Floor,

Department of Paediatric and Preventive Dentistry,

Government College of Dentistry, Indore, Madhya pradesh, India – 452001

**Mobile** - 9644015383

**Email** - anushadixit1234@gmail.com

## Abstract

**Background:** Thalassemia is a hereditary disorder that impairs hemoglobin synthesis, leading to anemia, fatigue, delayed growth and craniofacial deformities. The most severe form, thalassemia major, typically manifests in early childhood and has extensive systemic and developmental impacts. Orofacial manifestations, including widely spaced teeth, pale gingiva and decreased salivary immunoglobulin A (IgA), compromise oral immune defense. Consequently, individuals with thalassemia exhibit a heightened susceptibility to gingivitis, dental caries, and other periodontal diseases, often exacerbated by structural anomalies and limitations in routine dental care.

**Aim:**

Evaluation of Relationship Between the White Blood Cell Count and the Gingival Health (OHI-S) of Children with Beta Thalassemia Major.

**Objective:**

- To check the oral health status (GI & OHI-S) of the children suffering from Beta Thalassemia Major.
- To check the plaque index (PI) of the children suffering from Beta Thalassemia Major.

**Material & Methodology:** An observational study was conducted with a total sample of 114 children, aged 3 to 15 years, randomly selected from Thalassemia day care unit of a government hospital. An intraoral examination was conducted to assess their OHI-S (J.C Greene and J.R Vermillion), Plaque Index (Loe and Silness) and Gingival Index (Loe and Silness). Additionally, a complete blood examination was performed to check the total leukocyte count. The data were evaluated and processed with the help of SPSS version 25.

**Result:** There was a very weak, non-significant negative correlation between gingival score and WBC count (p-value-0.53). Subjects with low WBC counts had significantly higher OHI-S scores (p-value-0.21), though the differences in plaque and gingival scores were not statistically significant (p-value-0.75, p-value-0.325 respectively).

**Conclusion:** The findings suggest that subjects with low WBC counts had higher OHI-S scores, indicating a possible link between lower WBC counts and poor oral hygiene. However, the weak negative correlation between gingival scores and WBC count was not statistically significant, implying that the impact of WBC count on gingival health is minimal.

**Keywords:**  $\beta$ -Thalassemia Major; Gingivitis; WBC count; Relationship of WBC count and Gingivitis.

**INTRODUCTION**

Thalassemia, a genetic hematologic disorder first characterized by Dr. Thomas Cooley in 1925, results from defects in the synthesis of hemoglobin polypeptide chains, primarily affecting the alpha ( $\alpha$ ) or gamma ( $\gamma$ ) globin chains. These deficiencies disrupt normal erythropoiesis and accelerate red blood cell turnover, leading to chronic anemia.<sup>[1]</sup> Thalassemia is categorized into homozygous, heterozygous, and compound heterozygous types based on clinical manifestations and genetic profiles, with thalassemia major being the most severe phenotype. Typically manifesting in early childhood, thalassemia major results in profound anemia, delayed physical growth and systemic complications such as craniofacial abnormalities, fatigue, dyspnea and jaundice.<sup>[2]</sup>

The orofacial manifestations in thalassemia are significant, including dental malocclusions, widely spaced teeth, maxillary protrusion and distinctive craniofacial abnormalities linked to compensatory bone marrow expansion. These structural changes are frequently accompanied by secondary oral health challenges, such as an increased risk of dental caries,

gingival pallor, xerostomia, and decreased salivary immunoglobulin A (IgA) levels, which collectively impair salivary defenses and complicate oral health management for affected patients.<sup>[3]</sup>

Research indicates that children with beta-thalassemia major (BTM) have a higher prevalence of gingivitis compared to non-affected peers, largely due to systemic immune deficiencies and diminished salivary defense mechanisms. These patients exhibit reduced B lymphocyte activity and lower salivary IgA levels, both of which undermine their resistance to oral infections.<sup>[4]</sup>

Consequently, individuals with thalassemia are at a significantly increased risk of developing dental caries, periodontal disease and other oral infections. This heightened susceptibility is compounded by the chronic nature of the disease, barriers to routine dental care, limited oral health awareness, dietary imbalances and structural oral anomalies that make maintaining hygiene more challenging.<sup>[5]</sup>

This study aims to evaluate the relationship between the white blood cell count and the gingival health (OHI-S) of children aged 3-15 years with Beta Thalassemia Major.

## MATERIAL AND METHODOLOGY

### Sample Selection

An observational study was conducted with a total sample of 114 children, aged 3 to 15 years, randomly selected from thalassemia day care unit of a government hospital.

### Inclusion criteria

1. Children diagnosed with beta thalassemia major.
2. Children aged 3 to 15 years.
3. Children undergoing blood transfusions.
4. Children not planned for a bone marrow transplant.
5. Children with no other systemic diseases.
6. Children whose parents provided consent to participate in the study.

### Exclusion Criteria

1. Children not undergoing blood transfusions.
2. Children planned for a bone marrow transplant.
3. Children with other systemic diseases.

### Clinical Parameters

An intraoral examination was conducted to assess oral hygiene status using the Oral Hygiene Index Simplified (J.C. Greene and J.R. Vermillion, 1964)<sup>[6]</sup>, as well as the Plaque Index (Silness and Loe) and Gingival Index (Loe and Silness)<sup>[7]</sup>. In addition, a complete blood cell count was carried out to measure the total leukocyte count.

The oral hygiene assessment was based on the Oral Hygiene Index Simplified, which evaluates six specific index teeth for debris and calculus buildup. The Plaque Index involved inspecting four gingival areas of each selected tooth—the disto-facial, facial, mesio-facial, and lingual surfaces. The Gingival Index was used to determine the severity of gingivitis on these same teeth. <sup>[8]</sup>

Autoclaved plane mouth mirrors and explorers were utilized for the oral cavity examination. A single examiner and a single recorder were consistently employed throughout the study period to ensure uniformity.

### Statistical Analysis

The data were organized in an Excel sheet and processed using SPSS version 25.0 (Statistical Package for the Social Sciences). The Shapiro-Wilk test was employed to assess the probability distribution, which indicated that the data were not normally distributed. Consequently, non-parametric tests of significance were applied. Descriptive statistics were performed, and inter-group comparisons were conducted using the Kruskal-Wallis test. A p-value <0.05 was interpreted as the threshold for statistical significance.

### Results

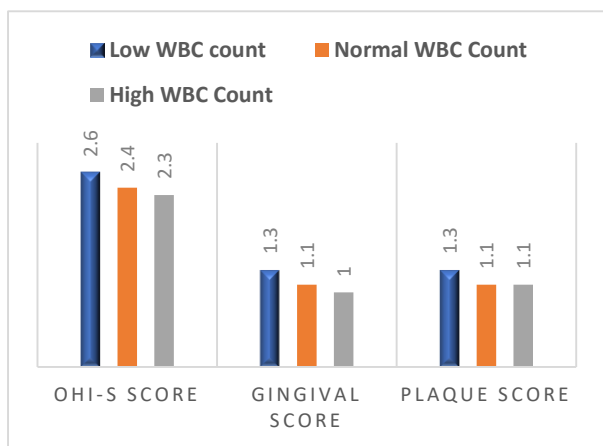
The median age of the participants was 11 years, with an interquartile range of 7 to 14 years. Most of the participants were aged between 11 and 15 years. Out of 114 participants, 76 (66.1%) were male and 39 (33.9%) were female. Most participants had normal white blood cell (WBC) counts (58.8%), while 22.8% had low WBC counts and 18.4% had elevated counts. The Oral Hygiene Index Simplified (OHI-S) score was significantly higher in subjects with low WBC counts compared to those with elevated counts. Although plaque and gingival scores were also highest in the low WBC group, the differences were not statistically significant ( $p > 0.05$ ) (Table 1, Figures 1 and 2). Furthermore, a very weak negative correlation was observed between gingival scores and WBC counts, which was not statistically significant ( $p > 0.05$ ) (Figure 3).

**Table 1. OHI-S, plaque index score and gingival index score of the subjects.**

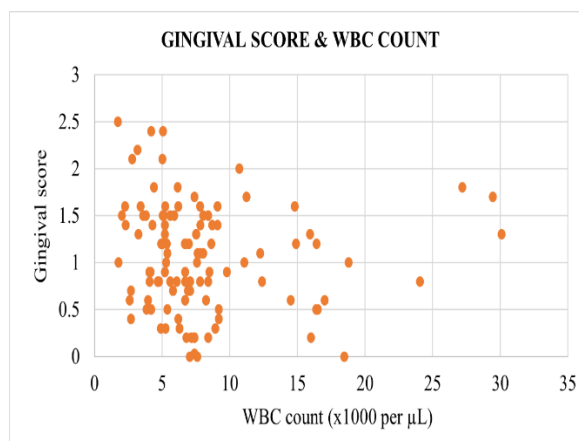
Variable	All subjects	WBC count			p-value
		Low	Normal	High	
OHI-S score	2.5 (1.8- 2.8)	2.6 (2.4- 3.8)	2.4 (1.6- 2.7)	2.3 (1.9- 2.8)	.021*
Plaque score	1.2 (0.8- 1.5)	1.3 (1.0- 1.8)	1.1 (0.8- 1.4)	1.1 (0.8- 1.6)	.074
Gingival score	1.0 (0.6- 1.5)	1.1 (0.6- 1.6)	1.1 (0.6- 1.5)	1.0 (0.5- 1.3)	.352

Kruskal-Wallis test. \*p-value<.05 was considered statistically significant.

**Figure 1. OHI-S Score, Gingival Score and Plaque Score .**



**Figure 2. Correlation between gingival score & WBC count.**



## DISCUSSION

This study aimed to assess the relationship between white blood cell (WBC) count and gingival health, alongside evaluating Oral Hygiene Status, Plaque Index and Gingival Index in children aged 3 to 15 years diagnosed with Beta-Thalassemia major. The findings highlight the substantial oral health challenges faced by this vulnerable population and illustrate the interconnectedness of systemic health and oral hygiene practices.

Beta-thalassemia major is a chronic hematological disorder characterized by ineffective erythropoiesis, leading to varying degrees of anemia and multi-system complications. A significant consequence of this condition is its impact on the immune system, which can worsen oral health issues.<sup>[9]</sup> In this study, a large proportion of participants exhibited poor oral hygiene, as indicated by elevated scores in the Oral Hygiene Index Simplified (OHI-S), Plaque Index (PI), and Gingival Index (GI). These results align with studies conducted by Singh *et al.* (2013) in India, Akcail *et al.* (2015) in Turkey and Das *et al.* (2024), which reported a higher prevalence of gingivitis and plaque in children with thalassemia compared to healthy peers, with statistically significant differences. This suggests that children with chronic illnesses may prioritize managing their systemic health over maintaining oral hygiene, contributing to a further decline in their oral health.<sup>[10,11,12]</sup>

The findings of this study are in contrast with those reported by Caliskan *et al.* (2011), Hattab *et al.* (2012) and Shadlinskaya *et al.* (2020), which did not

find significant differences in gingivitis or plaque accumulation. These discrepancies may be due to differences in study design, sample size, or population characteristics. Nonetheless, it is clear that individuals with beta-thalassemia are at a greater risk of oral health complications, emphasizing the need for comprehensive dental care, regular monitoring and focused management of contributing factors.<sup>[13,14,15]</sup>

Additionally, xerostomia (dry mouth), a common problem in thalassemia patients, further complicates oral hygiene maintenance. Saliva plays a critical role in neutralizing acids, removing food particles and providing antimicrobial properties. Consequently, these factors collectively heighten the risk of periodontal disease and other oral infections, accelerating the overall deterioration of oral health in children with beta-thalassemia major.<sup>[16,17]</sup>

Furthermore, the impaired immune response in these patients characterized by inadequate B lymphocyte activity and unchanged salivary immunoglobulin levels reduces their ability to effectively combat gingival inflammation. As a result, children with beta-thalassemia are less able to rely on the salivary immune defenses that are typically critical for preventing gingivitis and other oral infections.<sup>[18]</sup>

It is also important to consider the psychosocial factors that may affect the oral health of children with beta-thalassemia. Chronic illness can place significant emotional and psychological stress on both patients and their families, often resulting in a reduced quality of life. This stress can lead to the neglect of preventive health measures, such as oral

hygiene. The focus on managing systemic health can overshadow the importance of maintaining good oral health practices, perpetuating a cycle of neglect that worsens dental problems.<sup>[19]</sup>

Although this study identified a weak, statistically non-significant negative correlation between gingival scores and WBC count, this observation warrants further investigation. The complexity of the relationship between systemic health and oral hygiene may be influenced by additional factors, such as age, dietary habits, and overall health status. For instance, dietary imbalances related to thalassemia and its treatments can exacerbate oral health issues, increasing the risk of dental caries and periodontal diseases. Additionally, structural anomalies like malocclusion, commonly observed in thalassemia patients, can hinder effective oral

hygiene practices, compounding the oral health challenges faced by these individuals.

## CONCLUSION

This study evaluates the link between WBC count, oral hygiene, plaque index and gingival health in children with beta-thalassemia major. The results highlight the need for regular dental check-ups, targeted education on oral hygiene and specific interventions to address their unique challenges. Integrating dental care into the overall management of beta-thalassemia could improve both systemic and oral health, enhancing patient quality of life. Future research should explore larger cohorts and investigate the mechanisms behind oral health deterioration in these children, to develop more effective care strategies.

## BIBLIOGRAPHY

1. Majd Ibraheem, Bassam Salman. Comparative evaluation of oral health status in children with  $\beta$ -thalassemia major in latakia city - Syria. *Int J Dentistry Oral Sci.* 2021;08(03):1746-1750.
2. Nabi AT, Muttu J, Chhapparwal A, Mukhopadhyay A, Pattnaik SJ, Choudhary P. Implications of  $\beta$ -thalassemia on oral health status in patients: A cross-sectional study. *J Family Med Prim Care.* 2022;3(11):74-78.
3. Abdullarim RD, Gaphor MS. Prevalence of oral manifestation of thalassaemic patients in sulaymaniyah thalassemia center. *Tikrit Journal for Dental Sciences.* 2023;11(1): 93-104.
4. Rani ST, Reddy ER, et al. Comparative evaluation of BMI, Dental Age, Salivary Alkaline Phosphatase Levels, and Oral Health Status in children with  $\beta$  thalassemia major. *Int J Clin Pediatr Dent.* 2019;12(4):303-306.
5. Nabi AT, Muttu J, Chhapparwal A, Mukhopadhyay A, Pattnaik SJ, Choudhary P. Implications of  $\beta$ -thalassemia on oral health status in patients: A cross-sectional study. *J Family Med Prime Care.* 2022;3(11):74-78.
6. Greene JC, Vermillion JR. The oral hygiene index: a method for classifying oral hygiene status. *J Am Dent Assoc.* 1964; 68:7-13.
7. Loe H. The Gingival index, Plaque index and The retention index systems. *J Periodontol.* 1967;38(6): 610-616.
8. Peter S. Essentials of public health dentistry. 6<sup>th</sup> ed. New Delhi: Arya Medi Publishing House Pvt.Ltd; 2017.
9. Brzozka GA, Franczyk B, Gorzyska RM, Rokicki R, Rosciszewska KM, Rysz J. Pathomechanisms of immunological disturbances in  $\beta$ -thalassemia. *Int J Mol Sci.* 2021 Sep; 22(18): 9677.
10. Singh J, Singh N, Kumar A, Kedia NB, Agarwal A. Dental and periodontal health status of beta thalassemia major and sickle cell anemic patients: a comparative study. *J Int Oral Health.* 2013 Oct; 5(5): 53-8.
11. Akcali A, Kahraman Çeneli S, Gümüş P, Buduneli N, Lappin DF, Özçaka Ö. The association between thalassemia major and periodontal Health. *J Periodontol.* 2015 Sep; 86(9): 1047-57.
12. Das MS, Das U, Bhattacharjee S, Datta P. Oral hygiene status and dental caries experience in transfusion dependent thalassemia patients: An analytical cross-sectional study. *J Public Health Res Dev.* 2024; 15(30).
13. Caliskan U, Tonguc Mo, Ciris M, Balta N, Kirzioglu FY, Caglayan G, et al. The investigation of gingival iron accumulation in thalassemia major patients. *J Pediatr Hematol Oncol.* 2011;33(2):98-102.
14. Hattab FN. Periodontal condition and orofacial changes in patients with thalassemia major: a clinical and radiographic overview. *J Clin Pediatr Dent.* 2012; 36(3): 301-7.

15. Shadlinskaya RV. Evaluation of oral hygiene and dental caries status in patients with beta thalassemia. *World Med Biol.* 2020; 16(71): 145-141.
16. Rao GV, Preethi V, Daneswari V, et al. A comparative study of salivary flow rate, pH, buffer capacity, total antioxidant capacity, and ferritin levels in children with beta thalassemia major and healthy children. *Int J Clin Pediatr Dent.* 2021;14(3):342–348.
17. Dewi PRS, Septhimoranie S, Muchzal S. Correlation of saliva characteristics and caries in beta-thalassemia major patients. *Maj kedokt gigi Indones.* 2020; 6(2):100-105.
18. Yousif SS, Salih AB. Evaluation of Salivary Immunoglobulin A, and Iron Ion in relation to dental caries among children with beta thalassemia major(Karbala/Iraq) (Part One). *Ann Romanian Soc Cell Biol.* 2021;25 (7):314-318.
19. Fadel TH, Zolaly AM, Alharbi O M, Qarah AL, Alrehili SM, et al. Oral health profiles and related quality of life in thalassemia children in relation to iron overload: A cross-sectional study. *Int J Environ Res Public Health.* 2020, 17(24): 9444.



# Evaluation of Postoperative Pain after the Use of 5.25% Sodium Hypochlorite Gel, Solution at Room Temperature & Heated Solution Form at 50°C as Intracanal Irrigant: In Vivo Study

Dr. Irshad Ali, <sup>1</sup> Dr. Shahina Parvez, <sup>2</sup> Dr. Manoj Kumar Agarwal, <sup>3</sup> Dr. Rohit Kumar Khatri, <sup>4</sup> Dr. Lalit Kumar Likhyan, <sup>5</sup> Dr. Deepak Goel <sup>6</sup>

**1. Dr. Irshad Ali**

Post Graduate student, Department of Conservative Dentistry & Endodontics, RUHS College of Dental Sciences, Jaipur, Rajasthan, India

**2. Dr. Shahina Parvez**

Senior Professor, Department of Conservative Dentistry & Endodontics, RUHS College of Dental Sciences, Jaipur, Rajasthan, India

**3. Dr. Manoj Kumar Agarwal**

Professor & H.O.D. Department of Conservative Dentistry & Endodontics, RUHS College of Dental Sciences, Jaipur, Rajasthan, India

**4. Dr. Rohit Kumar Khatri**

Professor, Department of Conservative Dentistry & Endodontics, RUHS College of Dental Sciences, Jaipur, Rajasthan, India

**5. Dr. Lalit Kumar Likhyan**

Professor, Department of Conservative Dentistry & Endodontics, RUHS College of Dental Sciences, Jaipur, Rajasthan, India

**6. Dr. Deepak Goel**

Professor, Department of Conservative Dentistry & Endodontics, RUHS College of Dental Sciences, Jaipur, Rajasthan, India

## CORRESPONDING AUTHOR

**Dr. Shahina Parvez**

Senior Professor,

Department of Conservative Dentistry & Endodontics,

RUHS College of Dental Sciences, Jaipur, Rajasthan, India

**Mobile** - 9414280790

**Email** - parvezdrshahina@yahoo.com

## Abstract

**Objective-** purpose of this study was to evaluate postoperative pain after the use of 5.25% sodium hypochlorite gel, solution at room temperature & heated solution form at 50°C as intracanal irrigant.

**Materials and methods-** A total of 90 patients were divided into 3 groups according to the form and temperature of 5.25% sodium hypochlorite for root canal irrigation in mandibular 1<sup>st</sup> and 2<sup>nd</sup> molars. Each group contained 30 patients that were randomly divided into groups. In group 1, root canals were irrigated with 5.25% NaOCl solution at room temperature. In group 2, the 5.25% NaOCl gel at room temperature was used for irrigation of root canals. In group 3, NaOCl solution preheated at 50°C was used for irrigation of root canals. The root canal treatments were completed and the participants were given instructions to record postoperative pain levels at 24, 48, and 72 hours and 1 week after treatment using VAS.

**Results-** Intergroup analysis revealed that VAS score values for postoperative pain were least for NaOCl solution at 50°C followed by NaOCl gel at room temperature and highest for NaOCl solution at room temperature. Although intergroup difference in VAS score values were statically non-significant. ( $p>0.05$ ).

**Conclusion-** Both solution and gel form of sodium hypochlorite can be used as irrigant and solution form of sodium hypochlorite can be either used at room temperature or heated. Increasing temperature has positive effects on properties of sodium hypochlorite solution.

## INTRODUCTION

Endodontic success is strictly related to the removal of pulp tissue and to the disinfection of root canal system. Irrigation of the root canals<sup>3</sup>, is an essential part of endodontic treatment because the complete elimination of microorganisms from the root canal system is impossible only with instrumentation because of complex structure of root canal system which contain accessory canals, lateral canal, apical deltas, isthmus and presence of microflora in dentinal tubules. Sodium hypochlorite (NaOCl) is the most common irrigant used in endodontics because of its physicochemical and antibacterial properties, and its unique ability to dissolve necrotic tissue remnants<sup>7</sup>. However, accidental extrusion of the solution into the periapical tissue can result in some serious complications such as; hemolysis, ulceration, allergic reaction and tissue necrosis<sup>4</sup> because of its cytotoxic properties<sup>2</sup> which lead to inflammation of periapical region<sup>8</sup> and results in pain, swelling and soft tissue necrosis<sup>4</sup>. To avoid these complications, gel form of the NaOCl can be proposed. Previously, it has been reported that the gel and solution both did not interfere in the EDTA solution's action. Additionally, Garcia et al have evaluated the effect of several forms of NaOCl on the microhardness of root canal dentin and reported that the NaOCl gel and solution forms have a similar effect on dentinal microhardness<sup>6</sup>. Moreover, the antibacterial effectiveness of NaOCl gel and solution forms were compared and it has been reported that the antibacterial efficacy of the NaOCl gel and solution forms were similar. However, the tissue dissolution capacity of the NaOCl solution was higher than the gel form<sup>7</sup>. Increasing temperature has a positive effect on the antibacterial and lytic action of NaOCl. In addition, heated NaOCl, solution removes organic debris from dentin crimps better than unheated solution<sup>26</sup>.

## MATERIALS AND METHODS

The ethical committee of RUHS College of Dental Sciences, Jaipur approved the study protocol with the proposal No. RUHS-CDS/EC/2022/PG-The/15 dated 11.08.2022. All the participants included in the study signed an informed consent form before undergoing the treatment. A total of 90 mandibular molars with symptomatic irreversible pulpitis were included in the study. Teeth were randomly divided into three groups based on the form and temperature of the sodium hypochlorite used for irrigation.

**Group I** - 5.25% Sodium hypochlorite solution at room temperature

**Group II** - 5.25% Sodium hypochlorite gel at room temperature

**Group III** - 5.25% Sodium hypochlorite solution heated at 50° C

Simple random sampling was used for dividing the individuals between the groups. Double-blinding technique (participants and data collector unaware of material) was used in the study. Teeth included in this study were mandibular 1<sup>st</sup> and 2<sup>nd</sup> molar with history of spontaneous, referred pain diagnosed as symptomatic irreversible pulpitis. All the cases were of primary root canal treatment. Teeth with root fracture, pathologic mobility beyond physiological limits, periodontal pocket depth more than 3 mm, apical periodontitis, swelling, abscess, intra or extra oral sinus were excluded. Patient's age range was between 18 to 60 years. Root canal treatment protocol was same for each tooth, the only difference was in irrigation protocol. Randomization was done by chit system. Then treatment was started with local anesthesia using 2% lignocaine. Rubber dam isolation was done and access cavity was prepared. Root canals orifices were negotiated with the help sharp of DG-16 explorer. Loups were used for magnification. After negotiation of all canals, coronal flaring was done, Canals were negotiated till full length using no. 10k file and apical patency were

established. Working length were determined using electronic apex locator and confirmed radiographically. After that cleaning and shaping was done using first glide path rotary files and then using different no. file with 4 % and 6 % taper according to need. In between sequential filing, irrigation was done. In this study irrigation was done by one of the three methods using 5.25% NaOCl. In group I, 5.25% NaOCl solution at room temperature was used as irrigation material. In group II, 5.25% NaOCl gel at room temperature & in group III, 5.25% NaOCl solution heated at 50° C was used for irrigation. Volume of NaOCl for irrigation was 1 ml for each canal. During irrigation endo-activator was used for activation of irrigation material. Final irrigation was done using 17 % EDTA solution. After that, root canals were dried using absorbent paper points and master cone radiograph were taken & obturation was done using AH plus root canal sealer. Final restoration were done using composite resin cements. No occlusal reduction was done to keep tooth in state of functional loading of occlusal forces. After finishing procedure VAS scale was explained to patient & asked to record pain after 24 hours, 48 hours, 72 hours and 1 week after treatment. Oral analgesic Diclofenac sodium and paracetamol combination tablet SOS was prescribed. Patients were recalled after 1 one week and checked for any pain, tenderness, swelling, sinus to evaluate outcome of treatment. Data were collected from all subjects and analysed.

## RESULTS

The study compared the Postoperative pain after the use of 5.25% NaOCl gel, solution at room temperature & heated solution forms. Total 90 patients were included in the study and were divided into three groups. Group I: 5.25% NaOCl solution at room temperature Group, II: 5.25% NaOCl gel at room temperature Group, III: 5.25% NaOCl solution at 50°C The postoperative pain levels at 24, 48, and 72 hours and 1 week after treatment using VAS were checked. The VAS values in Group I was 2.20±1.86, in Group II was 1.90±0.92 and in Group III was 1.77±0.82. One way ANOVA test used showed non-significant difference between groups with F score 0.887 & P score 0.415. After 48 hours, the VAS Values in Group I was 1.20±1.16, in Group II was 1.10±0.84 and in Group III was 0.97±0.61. One way ANOVA test used showed non-significant difference between groups with F score 0.508 & P score 0.664. After 72 hours, VAS values in Group I was 0.23±0.50, in Group II was 0.27±0.44 and in Group III was 0.17±0.37. One way ANOVA test used showed non-significant difference between groups with F score 1.38 & P score 0.244. After 1 Week, VAS values in Group I was 0.067±0.25, in Group II was 0.00±0.00 and in Group III, 0.00±0.00. One way ANOVA test used showed non-significant difference between groups with F score 2.07 & P score 0.132.

**Table 1: Comparison of pain Score between groups at 24 hours**

Group	N	Mean	Std. Deviation	F score	P Score
Group I	30	2.20	1.86	0.887	0.415 <sup>#</sup>
Group II	30	1.90	0.92		
Group III	30	1.77	0.82		

One way ANOVA, <sup>#</sup>Non significant

**Table 2: Comparison of pain Score between groups at 48 hours**

Group	N	Mean	Std. Deviation	F score	P Score
Group I	30	1.2000	1.15669	0.508	0.664 <sup>#</sup>
Group II	30	1.1000	.84486		
Group III	30	.9667	.61495		

One way ANOVA, <sup>#</sup>Non significant

**Table 3: Comparison of pain Score between groups at 72 hours**

Group	N	Mean	Std. Deviation	F score	P Score
Group I	30	.2333	.50401	1.381	0.664 <sup>#</sup>
Group II	30	.2667	.44978		
Group III	30	.1667	.37905		

One way ANOVA, #Non significant

**Table 4: Comparison of pain Score between groups after one week**

Group	N	Mean	Std. Deviation	F score	P Score
Group I	30	0.067	0.25	2.07	0.132 <sup>#</sup>
Group II	30	0.00	0.00		
Group III	30	0.00	0.00		

One way ANOVA, #Non significant

## DISCUSSION

Irreversible pulpitis<sup>12</sup>, is a clinical diagnosis based on subjective and objective findings. Symptomatic irreversible pulpitis is one of the most common cause of dental pain. The treatment modality in such cases is root canal treatment of involved tooth. Postoperative pain<sup>9,11</sup> may be due to apical extrusion of contaminated debris<sup>1</sup> or irrigation solution, intracanal procedure<sup>18</sup> or because of preoperative pain as body takes little time to remove inflammatory mediators from site of inflammation. In this study, all the teeth which were included were diagnosed as Symptomatic irreversible pulpitis<sup>16</sup> without apical periodontitis, pulpal necrosis, abscess, sinus, crown & / or root fracture etc. Irrigation material should be able to clean the canals, should have antibacterial properties and should be able to dissolve organic matter from complex root canal system especially in the areas where mechanical instrumentation is not possible. NaOCl has good antimicrobial properties<sup>7, 18</sup> and soft tissue dissolving properties<sup>7</sup>. NaOCl have been used in various concentrations<sup>21, 24</sup> available such as 0.5%, 1%, 2.5%, 3%, 5%, 5.25%. Out of them 5.25 % concentration is one of the most commonly used concentration of NaOCl for irrigation of root canal system. Gel formulation<sup>7, 21</sup> of NaOCl is also used and it is based on the theory that there are chances of extruding of sodium hypochlorite solution in periapical region while using solutions and this can be reduced by using gel formulation. Heating of sodium hypochlorite solution is based on the hypothesis is that heating of solution reduces the

surface tension enhances the reach of solution in fine accessory, lateral root canals and isthmus. Previous studies have concluded that increasing temperature of solution has positive effects on properties of sodium hypochlorite<sup>26</sup>. In our study irrigation was done first using sodium hypochlorite and final irrigation was done using 17% EDTA solution. Root canal treatment was completed in one visit in each of the subject & Patients were asked to record their pain using VAS pain score after 24 hours, 48 hours, 72 hours and 1 week. After 24 hours, mean values of VAS score were 2.20 for group-I, 1.90 for group-II, 1.77 for group-III. There was no significance difference among groups, although values were least for group-III, followed by group-II and maximum for group-I. This indicates that both gel and solution form of NaOCl were more or less similar effective but values were least for group-III which indicates that heated NaOCl solution provided best outcome. This can be explain by results of previous studies which conclude that increasing temperature enhances properties of NaOCl solution. Similarly, after 48 hours, mean values of VAS were least for group-III, followed by group-II and maximum for group-I. After 72 hours, mean values of VAS were 0.233 for group-I, 0.267 for group-II and 0.167 for group-III. More VAS score mean values in group-II (NaOCl gel group) may be explained by in vitro study conducted by L. Luz *et al* (2019) in which they concluded that NaOCl gel showed less soft tissue dissolution as compared to solution form. After 1 week, mean values of VAS score were 0.06 for group-I, 0.00 for group-II and III. There were no

significant difference among groups. In intra group comparison, mean values of VAS score for group-I were 2.20, 1.20, 0.233 and 0.06 after 24 hours, 48 hours, 72 hours and 1 week. There were significant reduction in values (P-value = .0001). This indicates significant reduction in postoperative pain in patients. For group-II mean values of VAS score were 1.90, 1.10, 0.267 and 0.00 after 24 hours, 48 hours, 72 hours and 1 week. There were significant reduction in values (P-value = .0001). For group-III mean values of VAS score were 1.77, 0.9667, 0.167 and 0.00 after 24 hours, 48 hours, 72 hours and 1 week. There were significant reduction in values (P-value = .0001). If we take mean values of VAS score after 24 hours as baseline data, pain scored recorded during 48 hours, 72 hours and 1 week showed significant reduction in each group. VAS score mean values for group-II were less than group-I and least for group-III.

All these values indicate that NaOCl can be used either as solution or gel and solution can be used at room temperature or preheated. Least values for preheated NaOCl solution group (group-III) may be due to reduction of surface tension of solution and better penetration in 3 dimensionally complex root canal anatomy<sup>25</sup>. Using gel formulations of NaOCl may reduce the chances of periapical extrusion of chemical and thus less inflammatory response leading to less pain. Previous in vitro studies indicate that gel formulations have less penetration in fine accessory and lateral canal systems and less tissue dissolution properties. Root canal system in posterior teeth specially is a complex root canal anatomy<sup>25</sup> containing not only more than one main root canals, but also contains accessory canals, lateral canals, isthmus, and apical deltas. In this 3 dimensional complex structure containing pulp

tissue, mechanical cleaning and shaping is not possible in entire volume, so there is big role of irrigation of root canal system<sup>3</sup>. Endodontic postoperative pain<sup>9, 11</sup> is affected by several factors such as preoperative pain level, the number of appointments, irrigation method, the method of the determination of the working length, type of the tooth, type of the instrument, movement kinematic of the instrument, extrusion of root canal filling material and apically extruded debris. Although there was no significant difference in postoperative pain between different groups but postoperative pain was reduced in NaOCl gel group and further in NaOCl pre-heated solution group. This could be due to less apical extrusion of NaOCl gel as compared to solution. More reduction of postoperative pain in NaOCl preheated solution could be due to decrease in surface tension that help the solution to reach in 3 dimensionally complex structures with narrow isthmus and accessory and lateral canals. There are few limitations of this study such as small sample size, limited time period and stricter inclusion, exclusion criteria, specific tooth type and subjective nature of postoperative pain which is influenced by multiple clinical factors. All these limitations of this study indicate that further detailed investigations are required with large sample size to evaluate the effect of form and temperature of sodium hypochlorite as intracanal irrigant.

## CONCLUSION

Considering the results of our study, both solution and gel form of sodium hypochlorite can be used as irrigant and solution form of sodium hypochlorite can be either used at room temperature or heated. Increasing temperature has positive effects on properties of sodium hypochlorite solution.

## BIBLIOGRAPHY

1. Siqueira JF Jr, Guimarães-Pinto T, Rôças IN. Effects of chemomechanical preparation with 2.5% sodium hypochlorite and intracanal medication with calcium hydroxide on cultivable bacteria in infected root canals. *J Endod* 2007; 33(7):800–5.
2. Gernhardt CR, Eppendorf K, Kozłowski A, Brandt M. Toxicity of concentrated sodium hypochlorite used as an endodontic irrigant. *Int Endod J* 2004; 37(4):272–80.
3. Zehnder M. Root canal irrigants. *J Endod* 2006; 32(5):389–98.
4. Pontes F, Pontes H, Adachi P, Rodini C, Almeida D, Pinto D Jr. Gingival and bone necrosis caused by accidental sodium hypochlorite injection instead of anaesthetic solution. *Int Endod J* 2008; 41(3):267–70.
5. Zand V, Lotfi M, Rahimi S, Mokhtari H, Kazemi A, Sakhamanesh V. A comparative scanning electron microscopic investigation of the smear layer after

- the use of sodium hypochlorite gel and solution forms as root canal irrigants. *J Endod* 2010; 36(7):1234–7.
6. Garcia AJ, Kuga MC, Palma-Dibb RG, S6 MV, Matsumoto MA, Faria G, et al. Effect of sodium hypochlorite under several formulations on root canal dentin microhardness. *J Investig Clin Dent* 2013; 4(4):229–32.
  7. Luz LB, Santana R, Prates AW, Froelich J, de Melo TA, Montagner F, et al. Antimicrobial action, pH, and tissue dissolution capacity of 2.5% sodium hypochlorite gel and solution. *J Health Biol Sci* 2019; 7(2):121–5.
  8. Tanomaru Filho M, Leonardo MR, Silva LA, Aníbal FF, Faccioli LH. Inflammatory response to different endodontic irrigating solutions. *Int Endod J* 2002; 35(9):735–9.
  9. Attar S, Bowles WR, Baisden MK, Hodges JS, McClanahan SB. Evaluation of pretreatment analgesia and endodontic treatment for postoperative endodontic pain. *J Endo* 2008; 34(6):652–5.
  10. Keskin C, Özdemir Ö, Uzun İ, Güler B. Effect of intracanal cryotherapy on pain after single-visit root canal treatment. *Aust Endod J* 2017; 43(2):83–8.
  11. Arslan H, Doğanay E, Karataş E, Ünlü MA, Ahmed HMA. Effect of low-level laser therapy on postoperative pain after root canal retreatment: a pre-liminary placebo-controlled, triple-blind, randomized clinical trial. *J Endod* 2017; 43(11):1765–9.
  12. Parirokh M, Rejabi AR, Ashouri R, Nakhaee N, Abbott PV, Gorjestani H. Effect of occlusal reduction on postoperative pain in teeth with irreversible pulpitis and mild tenderness to percussion. *J Endod* 2013; 39(1):1–5.
  13. Pasqualini D, Mollo L, Scotti N, Cantatore G, Castellucci A, Migliaretti G, et al. Postoperative pain after manual and mechanical glide path: a randomized clinical trial. *J Endod* 2012; 38(1):32–6.
  14. Tanalp J, Sunay H, Bayirli G. Cross-sectional evaluation of post-operative pain and flare-ups in endodontic treatments using a type of rotary instruments. *Acta Odontol Scand* 2013; 71(3-4):733–9.
  15. Erdem Hepsenoglu Y, Eyuboglu TF, Özcan M. Postoperative pain intensity after single- versus two-visit nonsurgical endodontic retreatment: a randomized clinical trial. *J Endod* 2018; 44(9):1339–46.
  16. Topçuoğlu HS, Topçuoğlu G, Arslan H. The effect of apical positive and negative pressure irrigation methods on postoperative pain in mandibular molar teeth with symptomatic irreversible pulpitis: a randomized clinical trial. *J Endod* 2018; 44(8):1210–5.
  17. Arslan H, Güven Y, Karataş E, Doğanay E. Effect of the simultaneous work-ing length control during root canal preparation on postoperative pain. *J Endod* 2017; santis
  18. Siqueira JF Jr, Rôças IN, Favieri A, Machado AG, Gahyva SM, Oliveira JC, et al. Incidence of postoperative pain after intracanal procedures based on an antimicrobial strategy. *J Endod* 2002; 28(6):457–60.
  19. Marins JS, Sassone LM, Fidel SR, Ribeiro DA. In vitro genotoxicity and cy-totoxicity in murine fibroblasts exposed to EDTA, NaOCl, MTAD and citric acid. *Braz Dent J* 2012; 23(5):527–33.
  20. Ashofteh Yazdi K, Sabeti M, Motahary P, Kolahdouzan A, Shayesteh M, Shokouhinejad N. Subcutaneous tissue responses to three endodontic irrigants: a comparative study. *Iran Endod J* 2012; 7(3):144–8.
  21. Zand V, Lotfi M, Soroush MH, Abdollahi AA, Sadeghi M, Mojadadi A. an-tibacterial efficacy of different concentrations of sodium hypochlorite gel and solution on enterococcus faecalis biofilm. *Iran Endod J* 2016; 11(4):315–9.
  22. Ma J, Wang Z, Shen Y, Haapasalo M. A new noninvasive model to study the effectiveness of dentin disinfection by using confocal laser scanning microscopy. *J Endod* 2011; 37(10):1380–5.
  23. Bystrom A, Sundqvist G. The antibacterial action of sodium hypochlorite and EDTA in 60 cases of endodontic therapy. *Int Endod J* 1985; 18(1):35–40.
  24. Verma N, Sangwan P, Tewari S, Duhan J. Effect of different concentrations of sodium hypochlorite on outcome of primary root canal treatment: a randomized controlled trial. *J Endod* 2019; 45(4):357–63.
  25. Patel S, Patel R, Foschi F, Mannocci F. The impact of different diagnostic imaging modalities on the evaluation of root canal anatomy and endodontic residents' stress levels: a clinical study. *J Endod* 2019; 45(4):406–13.
  26. Aarushi Sahai, Alpa Gupta, Dax Abraham, Vivek Aggarwal, Arundeeep Singh, Garima Sharma, Alka Gurawa Evaluation of postoperative pain using warm versus room temperature sodium hypochlorite as an irrigant in mandibular molars with irreversible pulpitis: A randomized controlled trial 2023 Jul-Aug;26(4):458-465.

# Comparative Evaluation of Behavioral Efficacy of 4% Articaine With 24 Gauge Needle in Buccal Nerve Block Compared to 2% Lignocaine With 20 Gauge Needle in Inferior Alveolar Nerve Block in Children With Dento - Alveolar Abscess

Dr. Jyoti Sharma, <sup>1</sup> Dr. Nitin Sharma,<sup>2</sup> Dr. Divya Gera, <sup>3</sup> Dr. Richa Ray Nagori, <sup>4</sup> Dr. Deepanshu Sharma, <sup>5</sup> Dr. Rajeev Soangra <sup>6</sup>

**1. Dr. Jyoti Sharma**

Post Graduate Student, Department of Pediatric and Preventive Dentistry, Rajasthan Dental College & Hospital, Jaipur, Rajasthan, India

**2. Dr. Nitin Sharma**

Professor and Head, Department of Pediatric and Preventive Dentistry, Rajasthan Dental College & Hospital, Jaipur, Rajasthan, India

**3. Dr. Divya Gera**

Assistant Professor, Department of Pediatric and Preventive Dentistry, Rajasthan Dental College & Hospital, Jaipur, Rajasthan, India

**4. Dr. Richa Ray Nagori**

Assistant Professor, Department of Pharmacology, Rajasthan Dental College & Hospital, Jaipur, Rajasthan, India

**5. Dr. Deepanshu Sharma**

PhD Scholar, Department of Public Health, Rajasthan Dental College & Hospital, Jaipur, Rajasthan, India

**6. Dr. Rajeev Soangra**

Assistant Professor, Department of Periodontology, RUHS College of Dental Sciences, Jaipur, Rajasthan, India

## CORRESPONDING AUTHOR

**Dr. Rajeev Soangra**

Assistant Professor,

Department of Periodontology,

RUHS College of Dental Sciences, Jaipur, Rajasthan, India

**Mobile** - +917737323235

**Email** – rajeevsoangra@gmail.com

## Abstract

**Introduction:** Pain management in pediatric dentistry is crucial for alleviating anxiety and facilitating successful dental procedures. This study aims to compare the anesthetic efficacy of 2% lignocaine with a 20-gauge needle in Inferior Alveolar Nerve Block (IANB) and 4% articaine with a 24-gauge needle in Buccal Nerve Block (BNB) during dento-alveolar abscess extraction, assessed using the Frankl Behavior Rating Scale.

**Method:** A 12-month randomized controlled trial involving 100 pediatric patients aged 5 to 11 was conducted. Patients were randomized into two groups receiving either lignocaine or articaine as local anesthetics. Behavior assessments were performed during injection and extraction procedures using the Frankl behavior rating scale. Post-operative evaluations were conducted after 24 hours.

**Result:** Results indicate no significant difference in behavior responses between the IANB+LI and BNB+LI techniques during both injection and extraction procedures. Both

techniques effectively managed behavior during pediatric dental procedures, with slight variations observed between injections and extractions.

**Conclusion:** In conclusion, both IANB+LI and BNB+LI techniques demonstrate comparable efficacy in managing behavior during pediatric dental extractions. The study provides valuable insights into optimizing local anesthetic techniques to enhance the dental experience for pediatric patients.

**Keywords:** Lignocaine, Articaine, Frankl Behavior Rating Scale

## INTRODUCTION

Local anesthetics offer patients pain-free dental care while lowering patient apprehension and anxiety.<sup>(1)</sup> Pain management in dentistry is crucial for lowering the anxiety and fear related to dental operations. Dentistry relies heavily on local anesthetics to manage pain, and there is a lot of ongoing research in developing safer and more potent local anesthetics.<sup>(2)</sup>

Pediatric dentists frequently deal with anxiety in their patients because young patients frequently refuse dental care out of fear of pain and damage. This anxiety is associated with unfavorable consequences, including a poor family attitude, a fear of pain and trauma, and the sense of unsatisfactory dental therapy.

Articaine Hydrochloride, first created in Germany in 1969, was first used for deep anesthesia in dental procedures. Clinical trials in 1971 demonstrated its effectiveness, with 2% articaine with 1:1,000,000 adrenaline outperforming 2% lignocaine. In 1984, it was rebranded as articaine. The US FDA approved Septocaine in 2000.<sup>(3)</sup>

Lignocaine, an amide local anesthetic, was first introduced in 1948.<sup>(2)</sup> It is available in various forms and concentrations. The kidneys excrete 80% of its metabolites, with a half-life of 1.6 hours. Lignocaine and epinephrine have maximum dosages of 6.6 mg/kg and 4.4 mg/kg, respectively. Lignocaine was invented by Nils Lofgren in 1943 and procaine by Alfred Einhorn in 1904.<sup>(4)</sup>

Deciduous teeth's dental pulp can be infected by decaying teeth, caries, or dental trauma. If neglected, caries can spread to the pulp, leading to tooth abscesses. Pulmonary necrosis can result from severe inflammation or death. Dental trauma can also cause damage to blood vessels and nerves.

The aim of this study is to compare and evaluate the anesthetic effects of 2% lignocaine with a 20 gauge needle in Inferior Alveolar Nerve Block

(IANB) and 4% articaine with a 24 gauge needle in Buccal Nerve Block (BNB) in cases of dento-alveolar abscess extraction. This will be done by using the Frankl Behavior Rating Scale.

## METHODS

### 1. STUDY DESIGN

In a randomized trial, the behavioral effectiveness of 2% lignocaine with a 20 gauge needle in inferior alveolar nerve block and 4% articaine with a 24 gauge needle in buccal nerve block were evaluated in children with dento-alveolar abscesses. Following the principles derived from the 2010 Consolidated Standards of Reporting Trials statement, patients who satisfied all inclusion criteria were randomized 1:1 to one of two therapeutic groups. The trial was approved by the institutional ethics committee (RDCH/Ethical/2021-24/174). Rajasthan Dental College and Hospital carried out a 12-month randomized controlled research with 100 healthy youngsters. The study included patient groups, radiographic tests, and oral exams. Patients were divided into groups and given 2% lignocaine and 4% articaine as anesthetic medications. The study included patient diagnosis, clinical examination, full history, and ethics committee approval. While preparing an anesthetic solution for the nerve block, assessments of behavior and pain were conducted. A day later, post-operative instructions were given and calls for follow-up were received. Before receiving their agreement, the parents or guardians were fully informed about the study's methodology.

### 1. INCLUSION CRITERIA

- children between the ages of 5 and 11
- Patients' consent
- Mental capacity for communication
- Deep dentinal caries with bone loss
- Tooth with history of illness or swelling necessitating extraction;



**2. EXCLUSION CRITERIA**

- Mental and physical disability
- Hypersensitivity to sulfurites or local anesthetics.
- A history of severe illness or behavioral issues.
- The patient is taking medicine.
- Injection site pathosis that is active.
- Unable to provide informed permission.

**3. SAMPLE SIZE**

- The sample size was determined using the API-INFO program. There were 100 patients in all. (For every group, 50 patients)

**4. RANDOMIZATION TECHNIQUE**

- Once the qualifying patients were chosen, they were divided into two groups at random: Group A received 2% lidocaine with a 20 gauge needle for an inferior alveolar nerve block, whereas Group B received 4% articaine with a 24 gauge needle for a buccal nerve block. The kids in the research were seen by a single, skilled pediatric dentist in order to ignore inter-operator variability.

**5. ALLOCATION CONCEALMENT**

- A pediatric dentist who was not involved in the experiment assigned treatment sequence

alternatives based on the kind of intervention to every participant who was recruited using a lottery technique. Prior to treatment, the operator received the sealed envelopes with the recorded allocation results.

**6. SAMPLE GROUPING**

- Children were assigned randomly into two groups with 50 members each.
- Group 1 – 2% Lignocaine with 20 Gauge Needle in Inferior Alveolar Nerve Block
- Group 2 - 4% Articaine with 24 Gauge Needle Buccal Nerve Block

**7. BLINDING**

- The data analyst doing the analysis was blinded to the sorts of interventions, but the operating dentist did not hide the type of intervention. Prior to the study, the parents provided written informed permission. Every kid in every group received the same level of care and evaluation from the same dentist in the same environment to avoid bias.

**8. OPERATIVE PROCEDURES**

**Behavior Assessment** - Observed clinical parameters: behavior assessment on behavior on injection and extraction by using Frankl Behavior Rating Scale

Rating	Categories Of Behavior	Level Of Acceptance	Influence On Treatment
4	Active Physical Resistance , Protests Screaming , Refusal Of Treatment, Crying , Fearful	Definitely Negative No Acceptance	Treatment Can't Be Carried Out Without Physical Control
3	Crying, No Cooperation , Some Evidence Of Negative Attitude But Not Pronounced	Negative Acceptance	Treatment Can Be Carried Out Without Undue Delay, Raised Hands Interfering With The Treatment
2	Signs Of Resistance Such As Strained Muscles, Reserved Attitude, No Answer But Following Directions With Cooperation	Positive Reluctant Acceptance	Treatment Can Be Carried Out Without Undue Delay, Raised Hands But No Interference With The Treatment
1	Relaxed Calm Eyes, Talking And Showing Interest In The Procedure , Good Cooperation	Definitely Positive Acceptance	Treatment Can Be Carried Out Immediately (After Proper Information)

## RADIOGRAPHIC PARAMETERS

To make a diagnosis and rule out any other pathology, IOPA was obtained.

## OPERATIVE PROCEDURE

### GROUP A - 2% Lignocaine with 20 Gauge Needle in Inferior Alveolar Nerve Block

To provide a sanitary environment, the patient was draped. Subsequently, the local infiltration and inferior alveolar nerve block anesthetic solutions were made. To direct the penetration of the needle and the injection of the fluid, landmarks were highlighted. The nerve block procedure went well, and the patient's behavior and level of pain were monitored. This entailed keeping an eye on their behavior and assessing for discomfort throughout the injection. Throughout the course of the therapy, particularly during the extraction procedure, the level of discomfort and behavior were regularly monitored. The patient received post-operative instructions. Furthermore, a telephone follow-up was done a day later to make sure they were okay.

### GROUP B - 4% Articaine with 24 Gauge Needle in Buccal Nerve Block

To maintain sterility, the patient was draped. The anesthetic solutions for the local infiltration and buccal nerve block were then made. To help with

the needle penetration and solution injection, landmarks were indicated. The nerve block was effectively performed, and the procedure included an evaluation of the patient's behavior and level of discomfort. This involved observing their behavior and feeling for discomfort throughout the injection. Pain and behavior were monitored at every stage of the therapy, especially when the extraction was being done. The patient received instructions for following surgery. Furthermore, a telephone follow-up was done a day later to make sure they were okay.

**INTERVALS OF EVALUATION** - Anesthesia injection pain was quantified, and extraction operation pain was assessed.

### AFTER OPERATIVE REPORTING

A 24-hour post-operative evaluation was conducted on the patient in order to document behavior using frankl behavior rating scale. About their child's suffering, bites, numbness, and length of numbness, parents were questioned. Parents provided the data.

## 9. STATISTICAL ANALYSIS

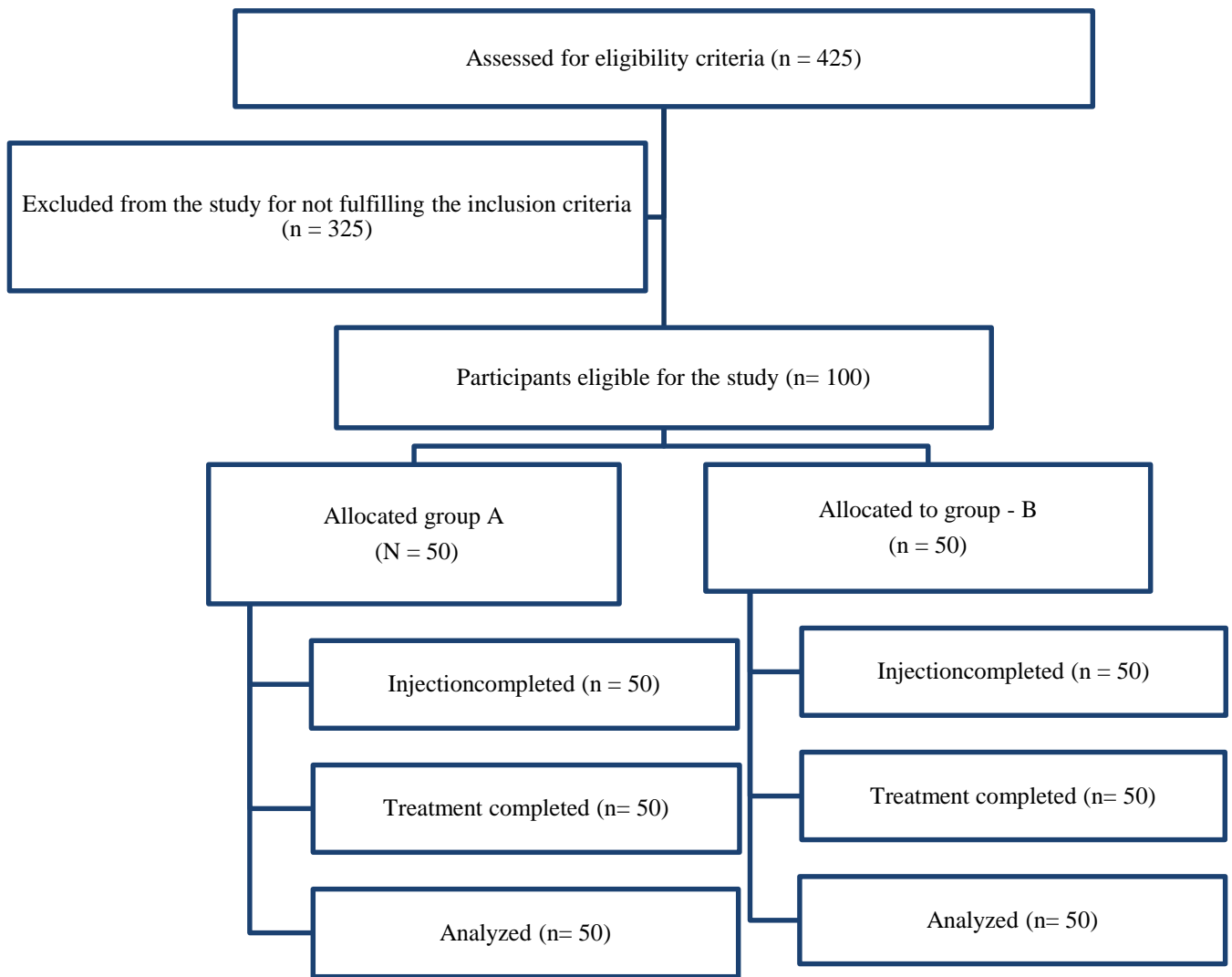
- SPSS was used to perform statistical analysis and describe the mean and sd value by descriptive analysis.

## RESULT

Table 1: Variable		IANB	BNB	P value	Overall
Age	Mean SD	8.94	8.32	2.7	0.62
Gender	Female	18 (36%)	15 (30%)	0.9	33 (33%)
	Male	32 (64%)	35 (70%)		67 (67%)

The study enrolled a total of 100 pediatric patients, with demographic characteristics evenly distributed among the treatment groups. There was a slight male predominance, with 67 males and 33 females

participating in the study. The mean age of the patients was 0.62 years (SD = 2.7), ranging from 5 to 11 years old. (table 1)



**Table 2: The behavior Assessment of the IANB+LI technique during the Injection of lignocaine was assessed using the Frankl Behavior Rating Scale for observational evaluation.**

	<b>Indicator</b>	<b>Frequency</b>	<b>Percent</b>	<b>Mean</b>	<b>SD</b>
<b>Frankl Behavior Rating scale</b>	Definitely Negative	7	14%	1.96	0.49
	Negative	38	76%		
	Positive	5	10%		
	Definitely Positive	0	0%		
	<b>Total</b>	<b>50</b>	<b>100%</b>		

**Table 3: The behavior Assessment of the IANB+LI technique during Extraction was assessed using the Frankl Behavior Rating scale for observational evaluation.**

	<b>Indicator</b>	<b>Frequency</b>	<b>Percent</b>	<b>Mean</b>	<b>SD</b>
<b>Frankl Behavior Rating scale</b>	Definitely Negative	1	2%	2.82	0.43
	Negative	7	14%		
	Positive	42	84%		
	Definitely Positive	0	0%		
	<b>Total</b>	<b>50</b>	<b>100%</b>		

The behavior of the child was assessed during the IANB + LI and BNB + LI techniques using the Frankl Behavior Rating Scale to measure the observed time.

Table 2 and 3, show that 5 children (10%) exhibited a positive response with no behaviour change during Lignocaine injection, while none showed a positive response during extraction. Positive responses were observed in 42 children

(84%) during extraction and 5 children (10%) during Lignocaine injection. The mean and p-value for Injection Lignocaine and Extraction were (1.96±0.49) and (2.82±0.43), respectively. The assessment of behavior during Lignocaine injection using the IANB + LI technique was conducted through observational evaluation using the Frankl Behavior Rating Scale.

**Table 4: The behavior Assessment of the BNB + LI technique during Injection Articaine was assessed using the Frankl Behavior Rating Scale for observational evaluation.**

	<b>Indicator</b>	<b>Frequency</b>	<b>Percent</b>	<b>Mean</b>	<b>SD</b>
<b>Frankl Behavior Rating scale</b>	Definitely Negative	4	8%	2.78	0.58
	Negative	3	6%		
	Positive	43	86%		
	Definitely Positive	0	0%		
	<b>Total</b>	<b>50</b>	<b>100%</b>		

**Table 5: The behavior Assessment of the BNB+LI technique during Extraction was assessed using the Frankl Behavior Rating Scale for observational evaluation.**

	<b>Indicator</b>	<b>Frequency</b>	<b>Percent</b>	<b>Mean</b>	<b>SD</b>
<b>Frankl Behavior Rating scale</b>	Definitely Negative	0	0%	3.5	0.61
	Negative	3	6%		
	Positive	19	38%		
	Definitely Positive	28	56%		
	<b>Total</b>	<b>50</b>	<b>100%</b>		

In Tables 4 and 5, 43 children (86%) demonstrated a positive response with no behavior change during Articaine injection, whereas 28 children (56%) exhibited a positive response during extraction. Negative responses were observed in 3 children (6%) during extraction and injection during

Process. The mean and p-value during injection and Extraction were (2.78±0.58) and (3.5±0.61), respectively. The evaluation of behavior during BNB + LI technique was conducted through observational assessment using the Frankl Behavior Rating Scale.

**Correlation:**

<b>Table 6: Behavior Significance between Frankl Behavior Rating Scale</b>		
<b>Indicator</b>	<b>Mean</b>	<b>SD</b>
<b>Behavior changes during injection and Extraction by IANB+LI Tech.</b>	0.16	0.01
<b>Behavior changes during injection and Extraction by BNB+LI Tech.</b>	1.08	0.00

Table 6 delineates the assessment of child behavior using the Frankl Behavior Rating scale throughout the IANB+LI process and extraction. Notable shifts in behavior were discernible during both the local anaesthesia administration and the extraction procedure. Specifically, a substantial alteration in

behavior, signifying significance at a P-value of 0.01, was evident during the IANB+LI Technique. However, in the context of BNB+LI, there was no statistically significant change in observed behavior.

<b>Table 7: The behaviour Assessment of the IANB+LI technique during Injection of Lignocaine by the 20-gauge needle was assessed using the Frankl Behaviour Rating Scale for observational evaluation.</b>					
<b>Frankl Behaviour Rating scale</b>	<b>Indicator</b>	<b>Frequency</b>	<b>Percent</b>	<b>Mean</b>	<b>SD</b>
	Definitely Negative	5	10%	2.06	0.54
	Negative	38	76%		
	Positive	6	12%		
	Definitely Positive	1	2%		
	<b>Total</b>	<b>50</b>	<b>100%</b>		

<b>Table 8: The behaviour Assessment of the BNB+LI technique during Injection Articaine by 24 gauge needle was assessed using the Frankl Behaviour Rating Scale for observational evaluation.</b>					
<b>Frankl Behaviour Rating scale</b>	<b>Indicator</b>	<b>Frequency</b>	<b>Percent</b>	<b>Mean</b>	<b>SD</b>
	Definitely Negative	0	0%	3.24	0.55
	Negative	3	6%		
	Positive	32	64%		
	Definitely Positive	15	30%		
	<b>Total</b>	<b>50</b>	<b>100%</b>		

In the Table 7, IANB+LI technique using a 20-gauge needle was evaluated for behavior during lignocaine injection using the Frankl Behavior Rating Scale. Results showed that 10% of patients were definitely negative, 76% were negative, 12% were positive, and 2% were definitely positive, with an overall mean score of 2.06 and a standard deviation of 0.54.

In the Table 8, Behavior Assessment of the BNB+LI technique during injection with Articaine by a 24-gauge needle, evaluated using the Frankl Behavior Rating Scale, indicated positive outcomes. The majority of children displayed positive (64%) or definitely positive (30%) behavior. The mean rating was 3.24 with a standard deviation of 0.55, highlighting generally favorable responses.

## **DISCUSSION**

Local anesthetics operate on the nerve membrane, with the particular receptor theory being the most widely recognized explanation. They reduce or completely remove sodium permeability by binding to specific receptors inside the sodium channel. <sup>(5)</sup> they are efficient at inhibiting high-frequency nerve impulses due to their ability to reach their site of action during the channel's inactive state.<sup>(6)</sup> Articaine, a 4% local anesthetic solution, is used in manufacturing due to its lower systemic toxicity and equivalent analgesic efficacy. It contains amide and ester groups, reducing toxicity through liver microsomal enzymes and plasma esterase hydrolysis. <sup>(7)</sup>

Pain control is crucial for children during invasive tooth extractions, and local anesthetic medication is commonly used to alleviate discomfort. However, children often react negatively to these injections, making painless treatment necessary. <sup>(8,9)</sup> Techniques to reduce pain include computerized systems, precooling, warming, and applying vibration or pressure on the injection site.<sup>(10)</sup> Dento-alveolar abscess is a small accumulation of pus in tooth tissues, resulting from tooth damage, poor dental care, or untreated dental caries. Bacterial invasion causes an inflammatory reaction, leading to pus collection and abscess development. Dentist appointments can be stressful, especially for children, who often display behavioral distress

indicators. According to Jean Piaget's cognitive theory, children between ages 4 and 11 are in the preoperational phase, while those between ages 7 and 11 are in the concrete operational phase. These children are naturally curious, intuitive, and require syllogistic reasoning, making them more challenging to manage. Behavior assessment in pediatric dentistry research and everyday clinical practice is accomplished using the Frankl Behavior Rating Scale.

The study assessed a child's behavior during dental treatment using the Frankl behavior rating scale. Dental fear and anxiety are common issues in pediatric dentistry, and behavioral ratings are crucial for classifying behavior and evaluating treatment. <sup>(11)</sup> The Frankl scale is brief and simple, but it lacks clinical details about difficult conduct. The study aimed to investigate children's acceptance of local anaesthetic dental treatment, parents' satisfaction with the procedure, and their child's impact. It also aimed to analyze the dental injection experience and compare two approaches (IANB and BNB) to determine which causes less discomfort or is more well-liked by the children.

Patients who had undergone the BNB+LI technique reported happiness during the injection procedure, and the sustained effect of articaine post-treatment contributed to a prolonged positive experience. These findings indicate that the BNB+LI technique may be considered a preferable option for minimizing negative behavioral responses during dental procedures. Halenur Alten et al (2021) studied that pain perception with a new needle-free system and dental needle method in children. During pulpotomy and restorative treatment, a needle-free system performed with 0.3 mL anesthesia was found as effective as infiltrative anesthesia with a dental needle method. <sup>(12)</sup> Similar to the present study, Pricila De Camargo Smolarek et al (2020) in their study evaluated the influence of different local anaesthetic techniques on pain, disruptive behavior, and anxiety in children's dental treatment. They concluded that different anaesthetic dental local techniques do not affect the levels of pain, disruptive behavior, anxiety, and physiological parameters in children aged 5–8 years old. <sup>(13)</sup>

Based on the statistical findings, it can be inferred that the BNB+LI technique is associated with a more favorable and stable behavioral response compared to the IANB+LI technique during injection. These results indicate that the BNB+LI technique may be considered a preferable option for minimizing negative behavioral responses during dental procedures or extraction procedures. Similar to the current study, Leila Erfanparast (2020) conducted a study to examine the impact of 2% lidocaine inferior alveolar nerve block and 4% articaine buccal infiltration on children's behavioral feedback and pain perception during pulp treatment of their mandibular second primary molar. They came to the conclusion that for pulp treatment of the second primary mandibular molars, buccal infiltration with 4% articaine produced an anaesthetic result that was similar to that of 2% lidocaine for inferior alveolar nerve block. <sup>(14)</sup> When extracting a mandibular primary molar bilaterally, Zahra Bahrololoomi et al. (2021) examined the anaesthetic effectiveness of a single buccal injection with 4% articaine in comparison to a standard inferior alveolar nerve block with 2% lidocaine. So, they came to the conclusion that an alternate method to the IANB for the extraction of primary mandibular molars may be the articaine infiltration approach. <sup>(15)</sup> According to the American Academy of Pediatrics (2011), a dentist's communication abilities have a significant impact on both patient satisfaction and behavior advice. According to Pinkham, behavior control is just as crucial as dexterity and knowledge, and both are essential for successful

clinical outcomes in pediatric dentistry. The majority of treated children in this trial showed positive outcomes and good behavior, this may be attributed to several factors:

- Good behavior management techniques employed.
- The high clinician's skill level and experience with children.
- Well-established relationship between the dentist and child/parents.
- Good case selection for the patients who fit very well with the trial inclusion criteria. <sup>(16)</sup>

## CONCLUSION

The study explores the use of local anesthetics, particularly articaine and lignocaine, in the context of tooth extraction in pediatric dentistry. Patient behavior is assessed using the Frankl behavior rating scale. The discussion highlights the importance of proper communication, behavior management techniques, and the dentist's skill level in influencing children's behavior and satisfaction during dental procedures. The study supports the growing trend favoring the use of articaine over lignocaine in pediatric dental anesthesia. To conclude, the study contributes valuable insights into the comparative efficacy of anesthetic techniques in pediatric dental extractions. The positive behavioral response associated with both the IANB+LI and BNB+LI techniques underscores their viability in managing pain and improving the overall experience for pediatric patients.

## DECLARATION OF INTEREST

The authors declare no conflicts of interest.

## BIBLIOGRAPHY

1. Rosenberg M. Handbook of Local Anesthesia, 5th Edition. Anesth Prog. 2005 Spring;52(1):39–40.
2. Katyal V. The efficacy and safety of articaine versus lignocaine in dental treatments: a meta-analysis. J Dent. 2010 Apr;38(4):307-17.
3. Martin E, Nimmo A, Lee A, Jennings E. Articaine in dentistry: an overview of the evidence and meta-analysis of the latest randomised controlled trials on articaine safety and efficacy compared to lidocaine for routine dental treatment. BDJ Open. 2021 Jul 17;7(1):27.
4. Barry Krall DDS (2011/12), Local Anesthesia Manual, Loma Linda University School of Dentistry.
5. Manchikanti L, Benyamin RM, Helm S, Hirsch JA. Evidence-based medicine, systematic reviews, and guidelines in interventional pain management: part 3: systematic reviews and meta-analyses of randomized trials. Pain Physician, 2009;12(1), 35-72.

6. Aggarwal V, Singla M, Kabi D. Comparative evaluation of effect of preoperative oral medication of ibuprofen and ketorolac on anaesthetic efficacy of inferior alveolar nerve block with lidocaine in patients with irreversible pulpitis: A prospective, double-blind, randomized clinical trial. *J Endod.* 2010;36:375-78.
7. Oertel R, Rahn R, Kirch W. Clinical pharmacokinetics of articaine. *Clinical pharmacokinetic.* 1997; 33 : 417 -25.
8. Odabaş ME, Çınar C, Deveci C, Alaçam A. Comparison of the anaesthetic efficacy of articaine and mepivacaine in pediatric patients: a randomized, double-blind study. *Pediatr Dent* 2012; 34: 42-5.
9. Kuscu OO, Akyuz S. Is it the injection device or the anxiety experienced that causes pain during dental local anaesthesia, *Int J Paediatr Dent* 2008; 18: 139-45.
10. Smolarek PC, Wambier LM, Siqueira Silva L, Chibinski ACR. Does computerized anaesthesia reduce pain during local anaesthesia in paediatric patients for dental treatment, A systematic review and meta-analysis. *Int J Paediatr Dent* 2020; 30: 118-35.
11. Frankl SN, Shiere FR, Fogels HR. Should the parent remain with the child in the dental operator J *Dent Child* 1962;29:150-163.
12. Bahrololoomi Z, Rezaei M. Anaesthetic efficacy of single buccal infiltration of 4% articaine compared to routine inferior alveolar nerve block with 2% lidocaine during bilateral extraction of mandibular primary molars: a randomized controlled trial. *J Dent Anesth Pain Med.* 2021 Feb;21(1):61-69.
13. Altan H, Belevcikli M, Coşgun A, Demir O. Comparative evaluation of pain perception with a new needle-free system and dental needle method in children: a randomized clinical trial. *BMC Anesthesiol.* 2021 Dec 1;21(1):301.
14. Erfanparast L, Rahbar M, Pourkazemi M, Vatandoust M, Balar S, Vafaei A. Comparison of Effects Exerted by 4% Articaine Buccal Infiltration and 2% Lidocaine Inferior Alveolar Nerve Block on Pain Perception and Behavioral Feedback of Children during Pulp Treatment of Mandibular Second Primary Molars. *Maedica (Bucur).* 2020 Dec;15(4):477-483.
15. Bahrololoomi Z, Rezaei M. Anaesthetic efficacy of single buccal infiltration of 4% articaine compared to routine inferior alveolar nerve block with 2% lidocaine during bilateral extraction of mandibular primary molars: a randomized controlled trial. *J Dent Anesth Pain Med.* 2021 Feb;21(1):61-69.
16. Pinkham JR. The roles of requests and promises in child patient management. *J Dent Child* 1993;60(3):169-74.



# Comparative Evaluation Of Dentinal Crack Formation After Using Protaper Universal, Protaper Gold, Hyflex EDM, And Neoendo Flex Rotary File Systems: An In Vitro Study

Dr. Mintu Maria Joseph, <sup>1</sup> Dr. Munish Singla, <sup>2</sup> Dr. Harleen Kaur, <sup>3</sup> Dr. Saloni Gupta, <sup>4</sup> Dr. Reetu Arora, <sup>5</sup> Dr. Vaani Mahajan <sup>6</sup>

- 1. Dr. Mintu Maria Joseph**  
Postgraduate Student, MDS, Department of Conservative Dentistry & Endodontics, Adesh Institute of Dental Sciences, Bathinda, Punjab, India
- 2. Dr. Munish Singla**  
Professor and Head, MDS, Department of Conservative Dentistry & Endodontics, Adesh Institute of Dental Sciences, Bathinda, Punjab, India
- 3. Dr. Harleen Kaur**  
Professor, MDS, Conservative and Endodontics, Adesh Institute of Dental Sciences, Bathinda, Punjab, India
- 4. Dr. Saloni Gupta**  
Reader, MDS, Conservative and Endodontics, Adesh Institute of Dental Sciences, Bathinda, Punjab, India
- 5. Dr. Reetu Arora**  
Senior Lecturer, MDS, Conservative and Endodontics, Adesh Institute of Dental Sciences, Bathinda, Bathinda, Punjab, India
- 6. Dr. Vaani Mahajan**  
Senior Lecturer, MDS, Conservative and Endodontics, Adesh Institute of Dental Sciences, Bathinda, Punjab, India

## CORRESPONDING AUTHOR

**Dr. Mintu Maria Joseph**

Plamkoothathil, Thiruvathukkal,

Kottayam Kerala - 686003

**Mobile** - 9495312270, 7975448184

**Email** - mintumariajoseph@gmail.com

## Abstract

**Background:** With newer advent of rotary systems being introduced to the market, the effect and comparison of these rotary systems on the radicular dentin always remain a topic of research. This study aims to compare and evaluate the frequency and amount of dentinal cracks after root canal instrumentation using ProTaper Universal, ProTaper Gold, HyFlex EDM, and Neoendo Flex rotary file systems using a digital stereomicroscope.

**Material and Methods:** A total of 80 extracted single-rooted mandibular premolars were selected with mature apices and straight canals and then randomly divided into four experimental groups (n = 20) according to the different rotary file systems used for preparation; Group 1: ProTaper Universal, Group 2: ProTaper Gold, Group 3: HyFlex EDM, Group 4: Neoendo flex. Sectioning was performed at 3, 6, and 9 mm from the apices. Digital images of the cut sample sections were viewed under a digital stereomicroscope of  $\times 25$  and  $\times 80$  magnification. Data was analyzed statistically using chi-square test.

**Results:** A statistically significant difference was found among all the groups ( $P < 0.01$ ). Group A (ProTaper Universal) showed the maximum percentage of dentinal cracks followed by other groups. In the intergroup comparison between the four groups, coronal 9mm sections showed an increased percentage of dentinal cracks which was statistically significant ( $P < 0.05$ ).

**Conclusion:** All the rotary systems after root canal preparation produced dentinal cracks. There was a significant difference between ProTaper Universal and other groups in terms of dentinal crack formation. The coronal sections had more frequency of cracks than other sections.

**Keywords:** Dentinal cracks, ProTaper Universal, ProTaper Gold, HyFlex EDM, Neoendo flex files

## INTRODUCTION

Utmost goal of endodontics is the elimination of microorganisms, pulp tissue, debris by enlarging the diameter of the original canal anatomy to a more desirable canal shape to obtain a proper seal. We axiomatically damage the root canal by procedural errors in the zest of cleaning and shaping procedure which serves as a pathway to craze line dentinal defects and vertical root fracture (VRF).

Walking from past to present, several instruments and techniques have been developed, rotary nickel-titanium (Ni-Ti) instruments with new design features with tip size, taper, helix angle, cross-section, and pitch are continually manufactured in an attempt to overcome canal preparation errors and have completely changed how routine root canal preparations are performed with the advantages of increased flexibility and shortened working time, while instrument separation and dentinal crack formation are its major disadvantages.<sup>1,2</sup>

Root canal preparation with rotary (Ni-Ti) instruments can significantly weaken the root by generating stresses in root dentin leading to microcracks or craze lines because of bending normal stresses and torsional shear stresses.<sup>3</sup>

This study aimed to evaluate the dentinal microcrack formation by a newer Ni-Ti file system in comparison with other rotary file systems in the field of endodontics using digital microscopic images.

### Methods:

The protocol was approved by the Ethical Committee for Biomedical & Health Research reference no. AU/EC\_BHR/2K22/154. Statistical sample size estimation was done by using GPower software (version 3.0). Sample size was estimated using  $\chi^2$  tests - Goodness-of-fit tests. A minimum total sample size of 76 (19 per group) was found to be

sufficient for an alpha of 0.05, power of 80%, 0.38 as effect size. To compensate for the loss of sample during the in vitro study, the sample size increased to 20 per group.

### Preparation of the samples

Single rooted mandibular premolars were collected for this study. Teeth with external cracks, severe curves or external defects, incompletely formed apex, and bifurcated canals were removed and replaced. Only straight and single canals ( $<5^\circ$ ) were included in the study. All the collected teeth specimens were washed and calculus and soft tissue were removed and were then stored in distilled water at room temperature till use.

### Preparation of the root canal

All the samples were decoronated using a low-speed saw under water coolant leaving around 16 mm root section for sufficient standardization. All the cut samples were tested using an operating microscope (DFOP-01 Denfort, India). The extracted teeth were decoronated at the cemento-enamel junction with a diamond disc to simplify access to the root canal. The decoronated teeth were then wrapped with aluminium foil (Hindalco Freshwrap) and mounted in acrylic resin (DPI RR Cold Cure). Once the acrylic was set, the teeth were removed, and foil was replaced with light body elastomeric impression material (3M ESPE Empress) to simulate the periodontal ligament.

Access was gained and a number 10 K-file (Dentsply Maillefer, Switzerland) was used to check the patency of the canal. The canal's working lengths were determined by inserting a size 10 K-file into the root canal terminus and subtracting 1 mm from this measurement.

### Instrumentation procedure

Eighty teeth were then randomly divided into four

experimental groups with 20 samples in each group according to the different rotary file systems used.

In group 1, samples were instrumented with ProTaper Universal in crown-down manner using 3-4 light brushing strokes at speed of 250rpm and torque 3Ncm for the shaping file SX (19/0.04) and S1(17/0.04), and speed 250rpm and torque 2.0 Ncm for shaping files S2(20/0.04), while for finishing file F1(20/0.07) and F2(25/0.08) the speed was 250rpm and torque 1.5Ncm.

In group 2, samples were instrumented using the ProTaper Gold system following the same sequence as ProTaper universal (group 1) was used, SX file (19/0.04), S1(18/0.02) and S2 (20/0.04)files, F1(20/0.07),F2 (25/0.08 )file till full working length. In group 3, samples were instrumented using HyFlex EDM file at speed 500rpm and 2.5Ncm, with slightly apical pressure and pecking motion. The sequence was 25/0.12 at coronal two-thirds of the working length, followed by 10/0.05 (glide path) and 25/~ (Onefile) till the working length.

In group 4, samples were instrumented using a set of Neoendo flex files at speed of 350rpm and 1.5 Ncm torque. The sequence followed was 30/0.08 for coronal flaring, followed by 17/0.04, 20/0.04, 25/0.04, 20/0.06 and 25/0.06 till working length.

All the samples in the four experimental groups were prepared with rotational motion using X-Smart motor (Dentsply-Maillefer,Switzerland) and instrumented with uniform tip diameter #25 and with the use of proper lubricant, EDTA gel (De smear, Anabond Stedman Pharma, India.). Canal irrigation was done using 3% NaOCl (Nova Dental Products Pvt. Ltd, Mumbai, India) (5 mL), employing a 30-gauge side-vented needle (Dispovan).

#### **Sectioning and microscopic analysis:**

Sectioning was performed in horizontal plane perpendicular to the long axis at 3, 6, and 9 mm from cemento-enamel junction using a diamond disc (DFOP-01 Denfort, India) under water coolant. A digital caliper (AR instrumented,Germany) was used to measure the slices to ensure uniform thickness of all slices. The cross sections were photographed under  $\times 25$  and  $\times 80$  magnification using a stereomicroscope (Olympus, Tokyo, Japan) attached to a digital camera. A total of 240 digital

images (60 per group) were obtained. A single examiner observed each sample to check the presence or absence of dentinal cracks.

The Scoring criteria was categorized into two groups. No cracks was defined as root dentin free of craze lines, cracks, or defects on the root surface (inner and outer). Cracks was defined as all lines and cracks observed, which were extended or not extended to the external root surface, for example, a craze line or a partial crack, and complete crack.

#### **RESULTS**

A chi-square test was performed to compare the incidence of dentinal cracks between the four groups. All statistical analyses were performed by using Statistical Package for Social Sciences, (SPSS) version 25.0. (SPSS Inc., Chicago, IL, USA). The level of significance was set at  $P = 0.05$ . Figure 1 depicts the presence of cracks in the cross-sections of the experimental groups.

Table 1 represents the comparison of dentinal cracks between all four groups. Group A (ProTaper Universal) showed the maximum percentage of dentinal cracks ( $P < 0.05$ ) followed by Group D (Neoendo Flex), Group B (ProTaper Gold), and Group C (HyFlex EDM) showed the lowest percentage of cracks.

Table 2 represents the intergroup comparison of cracks at different levels of the root. In the intergroup comparison between the four groups, coronal 9mm sections showed an increased percentage of dentinal cracks ( $P = 0.007$ ) followed by 6mm and 3mm which was statistically significant. ProTaper Universal had an overall appearance of cracks in all the three sections in comparison to other groups.

#### **DISCUSSION**

Momentary stress concentrations during canal enlargement using different techniques and the subsequent profound contact of instruments with dentin walls result in the initiation of dentinal defects. The higher frequency of defects in a material exponentially increases the risk of stress concentration during mechanical loading and potentially impairs the mechanical performance of the restorative assembly leading to catastrophic fracture under lower loads than the conventional nominal resistance, and that microcracks induced by different root canal preparation techniques could

compromise tooth mechanical performance during masticatory.<sup>4</sup>

Peter et al in their study concluded that the rotary and reciprocating files create microcracks in the radicular dentin ranging from 15% to 60% and the clinical prevalence of VRFs leading to tooth extraction of root filled teeth ranged from 8.8% to 13.4% according to various data.<sup>5,6</sup> In the present in vitro study, out of 240 samples evaluated for cracks, 12% of the samples showed dentinal cracks. There were no cracks in some samples of each group as in agreement with other studies depicting sectioning method had no effect on crack formation and also sectioning was carried out with water coolant which might have lead to this.<sup>6</sup> Sodium hypochlorite in a concentration of three percentage was used in this study as an attempt to preserve dentin mechanical properties.<sup>7</sup> For standardization of the canal anatomy, mandibular premolars with single roots were chosen.

Digital stereomicroscope aids in high-resolution digital photos, imaging qualities displayed in a larger format on a high-resolution provides for better accuracy, diagnostic precision, and qualitative evaluation than the conventional approaches. The time required for analysis with SEM was almost double that of a digital stereomicroscope which is an alternative in less demanding tasks.<sup>8</sup>

Numerous improvements and evolution of different generations of engine-driven nickel-titanium instruments in the past 20 years were observed in the geometric design, manufacturing surface treatment such as electropolishing, thermal treatment, and metallurgy.

ProTaper Universal (Dentsply –Maillefer, Ballaigues, Switzerland) represented a revolutionary progression in root canal preparation procedures. It was the first system to offer active cutting edges, a progressively tapered design on a single file, and both Shaping and Finishing files, made of the conventional Ni-Ti and ProTaper Gold (Dentsply –Maillefer), the next in the series of the ProTaper file system with the exact geometries as the former but fortuitously has been metallurgically enhanced through heat treatment technology leading to increased flexibility and cyclic fatigue. HyFlex EDM (Coltene, USA) is a 5th-generation rotary system that adapts the advantages of the

second and third generations. The most recent Neoendo Flex files (Orikam Health India Private Limited), is a third-generation rotary file with two file-shaping systems. According to the manufacturers, this system underwent proprietary heat treatment (Gold Thermal Treatment) that increases cutting efficiency and flexibility.

In the present study, ProTaper Universal rotary files demonstrated 20% dentinal defects as compared to ProTaper Gold (8.3%) Hyflex EDM (5%) and Neoendo (16.6%) .

The increased percentage of cracks found in the ProTaper Universal group maybe attributed to progressive taper design along with increased relative stiffness as these were manufactured using the conventional Ni-Ti wire which might have lead to more stress generation and concentration of stress especially in the apical root end comparing to Protaper Gold and Hyflex in accordance with Bergmans et al.<sup>9</sup>

Pirani et al in their study quoted HyFlex EDM with a variable cross-section design (from triangular to trapezoidal and quadratic) and EDM technology being used in their manufacturing which makes it extremely flexible and built-in memory which prevents stress during canal preparation by the change in their spiral shape and following the anatomy of the canal, thus creating fewer cracks.<sup>10</sup> Consequently, the overall lesser percentage of cracks in the HyFlex compared with other groups in this study might be related to these confounding factors.

There were more cracks in the coronal (9mm) of the root in all the groups which might have been produced by the orifice opener presenting with larger taper instruments generating forces on walls of oval canals of mandibular premolars and sacrificing more of normal dentine. These forces lead to the creation of stress and crack propagation on the weakened dentinal walls in the coronal sections.<sup>11,12</sup> The SX file of Protaper instruments exhibits nine increasingly larger tapers ranging from 3.5% to 19% between D1 and D9, and a fixed 2% taper between D10 and D14.<sup>13</sup>

Despite the 12% taper of HyFlex orifice opener files, the lesser percentage of cracks can be attributed to the increased rotational speed as recommended by the manufacturers. According to Peters et al the

increase in the rotational speed was associated with increased cutting efficiency and might be related to less crack formation.<sup>1</sup> An extended fatigue resistance and recommended speed of 500 rpm which is higher than the other instruments tested in the present study could be reason for overall decrease in cracks by Hyflex.

ProTaper Gold has a convex triangular cross-section geometry which decreases rotational friction between the blade of the file and dentin and its two-stage specific transformation behavior and high austenitic finishing temperatures similar to CM wire technology imparts more flexibility.<sup>14</sup> These findings are per the findings of Pedulla et al who concluded M wire and CM wire exhibit more flexibility than conventional Ni-Ti rotary instruments.<sup>1,15</sup>

The Protaper S1 file exhibits twelve increasingly larger tapers ranging from 2% to 11% between D1 and D14 and S2 file exhibits nine increasingly larger tapers ranging from 4% to 11.5% between D1 and D14. They are designed to prepare the coronal one-third of a canal and middle one-third respectively.<sup>13</sup> The increasingly larger tapers over the length of their cutting blades of shaping files might have lead to more cracks in Protaper universal and Protaper gold in the middle sections comparing to the other groups.<sup>11</sup>

The finishing file of Protaper instruments (F1) have fixed taper of 7% between D0 and D3 and from D4-D14 each instrument has increasing cross-sectional dimensions but over this same length, each instrument has a decreasing percentage taper. Decreasing the percentage taper over a portion of a files' cutting blades serves to improve flexibility, and reduces the potential for dangerous taper-lock.<sup>11,13</sup> This might have lead to comparatively lesser cracks in Protaper instruments in relation to the constant 6% taper along the whole length of the Neoendo flex files in the apical sections of samples. The cracks found in the sample prepared with Neoendo can be attributed to its triangular cross-

section along with the constant taper, and lack of shape memory feature can lead to increased torsional load and fatigue to file and also imparts more dentinal cracks.<sup>16</sup> The study done by Ananya et al analysed that because of the triangular cross-section, the file comes in contact with the dentin at 3 points which creates more tensile stress on the dentin wall leading to dentinal microcracks comparing to the convex triangular cross-sections of Protaper instruments where the contact stresses are less.<sup>17</sup> The increase in the mass and the contact points between the instrument surface and the dentin walls influence the flexibility of the Ni-Ti endodontic rotary files leading to excessive root canal dentine removal, apical transportation, root perforations, and fractures.<sup>18</sup>

Various speed and torque of the instruments were a limitation in this study as it could not be standardized. The forces during instrumentation could be considered for possible bias. More advanced technologies and simulation of similar oral and clinical conditions should be carried out for the assessment of dentinal cracks to conclude choosing a dentin-friendly file system.

## **CONCLUSION**

Within the limitations of this study, it can be concluded that all Ni-Ti files tested in this study may cause dentinal cracks on the root surface. The Contact stress levels created in the root dentin are determined by their cross-sectional, longitudinal design and the heat treatment undergone by the various file systems which play an integral role in crack formation and propagation. The overall frequency of cracks was more in Protaper universal files compared to Neoendo flex files followed by ProTaper Gold and Hyflex EDM files.

## **Clinical significance**

All the rotary systems tested in this invitro study produced dentinal cracks. These cracks create stresses in the dentinal walls which can propagate to vertical root fracture and ultimately lead to poor endodontic prognosis and failure.

## BIBLIOGRAPHY

1. Peters OA. Current challenges and concepts in the preparation of root canal systems: a review. *J Endod* 2004; 30:559-67.
2. Jacob J, Paul M, Sara B, Steaphen P, Philip N, Mathew J. Comparative Analysis of Dentinal Crack Formation Following Root Canal Instrumentation with Hand K-Flex Files, ProTaper Next, and Self-adjusting Files. *J Contemp Dent Pract* 2019; 20:935-939.
3. Devi TP, Kaur A, Priyadarshini S, Deepak BS, Banerjee S, Sanjeeta N. Microscopic Assessment of Dentinal Defects Induced by ProTaper Universal, ProTaper Gold, and Hyflex Electric Discharge Machining Rotary File Systems - An in vitro Study. *Contemp Clin Dent* 2021; 12:230-234.
4. Valle AD, Dotto L, Morgental RD, Pereira-Cenci T, Pereira GKDR, Sarkis-Onofre R. Influence of Root Canal Preparation on Formation of Dentinal Microcracks: A Systematic Review. *Braz Dent J* 2020; 31:201-220.
5. Peters OA, de Azevedo Bahia MG, Pereira ES. Contemporary Root Canal Preparation: Innovations in Biomechanics. *Dent Clin North Am* 2017; 61:37-58.
6. Versiani MA, Cavalcante DM, Belladonna FG, Silva EJNL, Souza EM, De-Deus G. A critical analysis of research methods and experimental models to study dentinal microcracks. *Int Endod J* 2022; 55:178-226.
7. Moorer WR, Wesselink PR. Factors promoting the tissue dissolving capability of sodium hypochlorite. *Int Endod J* 1982; 15:187-96.
8. Daher R, Krejci I, di Bella E, Marger L. Evaluation of the Validity of Digital Optical Microscopy in the Assessment of Marginal Adaptation of Dental Adhesive Interfaces. *Polymers (Basel)* 2021; 14:83.
9. Bergmans L, Cleynenbreugel JV, Beullens M, Wevers M, Meerbeek BV, Lambrechts P. Smooth flexible versus active tapered shaft design using NiTi rotary instruments. *Int Endod J* 2002; 35:820-8.
10. Pirani C, Iacono F, Generali L, Sassatelli P, Nucci C, Lusvardi L, et al. HyFlex EDM: superficial features, metallurgical analysis and fatigue resistance of innovative electro discharge machined NiTi rotary instruments. *Int Endod J* 2016; 49:483-93.
11. Bier CA, Shemesh H, Tanomaru-Filho M, Wesselink PR, Wu MK. The ability of different nickel-titanium rotary instruments to induce dentinal damage during canal preparation. *J Endod* 2009; 35:236-8.
12. Sindi F, Zahid A, Alghamdi F, Albassam A. The Incidence of Dentinal Microcracks in Single-Rooted Teeth Using Reciproc, One Curve, and Vortex Blue Endodontic File Systems: An In Vitro Study. *Journal of Research in Medical and Dental Science* 2021; 9:50-8.
13. Ruddle CJ. The ProTaper advantage: Shaping the future of endodontics. *Dentistry Today* 2001; 10:1-9.
14. Zan R, Tunç T, Hubbezoğlu İ, Sümer Z. Apical extrusion of intracanal biofilm using ProTaper Gold, WaveOne Gold, Twisted File Adaptive, OneShape New Generation and K3XF. *Eur Endod J* 2016; 1:1-6.
15. Pedullà E, Genovesi F, Rapisarda S, La Rosa GR, Grande NM, Plotino G, et al. Effects of 6 Single-File Systems on Dentinal Crack Formation. *J Endod* 2017; 43:456-461.
16. Chhabra A, Ramya KP, Prathap BS, Yadav P. Life span of Neoendo Flex and ProTaper Next rotary files with reciprocating motion in single-rooted teeth. *J Conserv Dent Endod* 2023; 26:420-423.
17. Guha A, Pandharikar R, Shivangi S, Rao RD, Verma M, Jain AK. Comparative evaluation of dentinal crack formation after root canal preparation with Neoendo Flex and Mani Silk files: An in vitro study. *J Conserv Dent* 2020; 23:468-472.
18. Faus-Llácer V, Hamoud-Kharrat N, Marhuenda Ramos MT, Faus-Matoses I, Zubizarreta-Macho Á, Ruiz Sánchez C, Faus-Matoses V. Influence of the Geometrical Cross-Section Design on the Dynamic Cyclic Fatigue Resistance of NiTi Endodontic Rotary Files-An In Vitro Study. *J Clin Med* 2021; 10:4713.

**Table 1: Overall cracks comparison among the study groups**


Group	No.of cracks present	No.of cracks absent	Chi-Square	p-value
	n(%)	n(%)		
Group A (Universal)	12(20)	48(80)	24.56	<0.01*
Group B (Gold)	5(8.33)	55(91.67)		
Group C (Hyflex)	3(5)	57(95)		
Group D (Neoendo)	10(16.67)	50(83.33)		

\*: statistically significant

**Table 2: Intergroup comparison of cracks at apical (3mm), middle (6mm) and coronal (9mm) among the study group.**

Levels	Groups	Present	Absent	Chi-square	p-value
		n (%)	n (%)		
Apical level (3mm)	Group A (Universal)	1(5)	19(95)	8.14	0.039*
	Group B (Gold)	0(0)	20(100)		
	Group C (Hyflex)	0(0)	20(100)		
	Group D (Neoendo)	3(15)	17(85)		
Middle level (6mm)	Group A (Universal)	3(15)	17(85)	8.14	0.039*
	Group B (Gold)	1(5)	19(95)		
	Group C (Hyflex)	0(0)	20(100)		
	Group D (Neoendo)	0(0)	20(100)		
Coronal level (9mm)	Group A (Universal)	8(40)	12(60)	11.23	0.007*
	Group B (Gold)	4(20)	16(80)		
	Group C (Hyflex)	3(15)	17(85)		
	Group D (Neoendo)	7(35)	13(65)		

\*: statistically significant



#### FIGURE LEGENDS

**Figure 1:** Cross section at 9-mm level (A and B), at 6mm (C and D), at 3mm(E and F) viewed under  $\times 80$  magnification. Visible cracks after Ni-Ti instrumentation(marked by red arrows)



# Dentin Bonding Unveiled: A Look at the Past, Present, and Future Innovations

**Dr. Tarunpreet Kaur Dhani,<sup>1</sup> Dr. Manisha Bhati,<sup>2</sup> Dr. Shantun Malhotra,<sup>3</sup>  
Dr. Kanwalpreet Kaur Bhullar<sup>4</sup>**

**1. Dr. Tarunpreet Kaur Dhani**

Postgraduate student, Department of Conservative Dentistry & Endodontics, SGRDIDSR, Amritsar, Punjab, India

**2. Dr. Manisha Bhati**

Specialist & Private practitioner, Department of Conservative Dentistry & Endodontics, Jodhpur, Rajasthan, India

**3. Dr. Shantun Malhotra**

Professor, Department of Conservative Dentistry & Endodontics, SGRDIDSR, Amritsar, Punjab, India

**4. Dr. Kanwalpreet Kaur Bhullar**

Professor & head, Department of Conservative Dentistry & Endodontics, SGRDIDSR Amritsar, Punjab, India

## CORRESPONDING AUTHOR

**Dr. Manisha Bhati**

Private practitioner & Specialist,  
Department of Conservative Dentistry & Endodontics,  
Jodhpur, Rajasthan, India

**Mobile** - +918094757022

**Email** – dr.bhatimanisha@gmail.com

## Abstract

### Abstract

Dentin bonding agents are designed to enhance the clinical effectiveness and longevity of resin-based restorations. Despite advancements in adhesive systems, the bonded interface remains the most vulnerable aspect of tooth-colored restorations. Earlier adhesives were prone to failures due to loss of retention and inadequate marginal adaptation. However, the advent of reliable adhesive materials has minimized the need for extensive tooth preparation, promoting a more conservative approach. Dentin bonding has undergone significant evolution, transitioning from no-etch to total-etch and self-etch systems. The introduction of self-etch primer adhesives has streamlined bonding procedures by eliminating the need for a separate etching step. Modern dental bonding systems are categorized as three-step systems (sequential application of etchant, primer, and adhesive), two-step systems (combined etchant and primer), and one-step systems (pre-mixed components applied in a single step), often referred to as seventh-generation bonding agents. This article delves into the mechanisms, advancements, and newer generations of bonding agents, including self-etch and total-etch systems, with a focus on their role in achieving durable and effective adhesive restorations.

**Keywords:** Dentin bonding agents, Hybrid layer, Enamel adhesion, Self-etch adhesives, Adhesive dentistry advances, Smear layer

## INTRODUCTION

Minimally invasive dentistry has replaced the traditional "drill and fill" approach, prioritizing the preservation of healthy tissue over artificial replacements. Adhesive materials have revolutionized clinical practice by enabling conservative cavity preparations and favoring repair over complete restoration replacement.<sup>1,2</sup>

Despite advancements, secondary caries at gingival margins, primarily due to unreliable dentin bonding, remain the leading cause of failure in moderate to large composite restorations. While enamel bonding is reliable, achieving a durable dentin bond remains challenging, with the resin-dentin interface often being the weakest link. Modern adhesive systems have improved retention, but robust dentin bonding continues to require innovation.<sup>3</sup>

Over the past four decades, advancements in adhesive monomers and dentin pre-treatment have enhanced dental adhesive technology, significantly improving restorative outcomes. This progress has shifted cavity preparation from G.V. Black's extension for prevention to a lesion-centered approach. Innovations in adhesive materials, caries detection, magnification, digital radiography, and risk assessment now support more conservative and effective caries management.

### History of Dentin Bonding Agents

In the early 1950s, research into materials capable of bonding resins to tooth structures began. The first notable development in adhesive dentistry was

achieved by Dr. Oskar Hagger, a Swiss chemist working for DeTrey/Amalgamated Dental Company. In 1951, he introduced the first dental adhesive product, "Sevriton Cavity Seal," which utilized glycerophosphoric acid dimethacrylate (GPDM) as its adhesive component.<sup>4</sup>

In 1952, a study by McLean and Kramer highlighted the potential of "Sevriton Cavity Seal," noting that GPDM improved dentin adhesion by penetrating the surface and forming an intermediate layer.<sup>5</sup>

**Buonocore et al (1955)** conducted experiments to enhance the adhesion of acrylic filling materials to enamel surfaces, a major limitation in restorative dentistry at the time. It was concluded that in intraoral tests, the treated surfaces exhibited significantly improved adhesion compared to untreated controls. This marked an early step toward understanding resin-to-tooth bonding mechanisms.<sup>6</sup>

The field took a revolutionary turn in 1955 with the work of Dr. Michael Buonocore, widely regarded as the pioneer of adhesive dentistry. Inspired by techniques used in the automotive industry, where phosphoric acid was applied to metal surfaces to enhance primer adhesion, Buonocore introduced the concept of acid-etching to dentistry. He demonstrated that treating enamel surfaces with phosphoric acid significantly improved resin adhesion. In his landmark research, Buonocore used 85% phosphoric acid, setting the foundation for modern adhesive dentistry.<sup>7</sup>

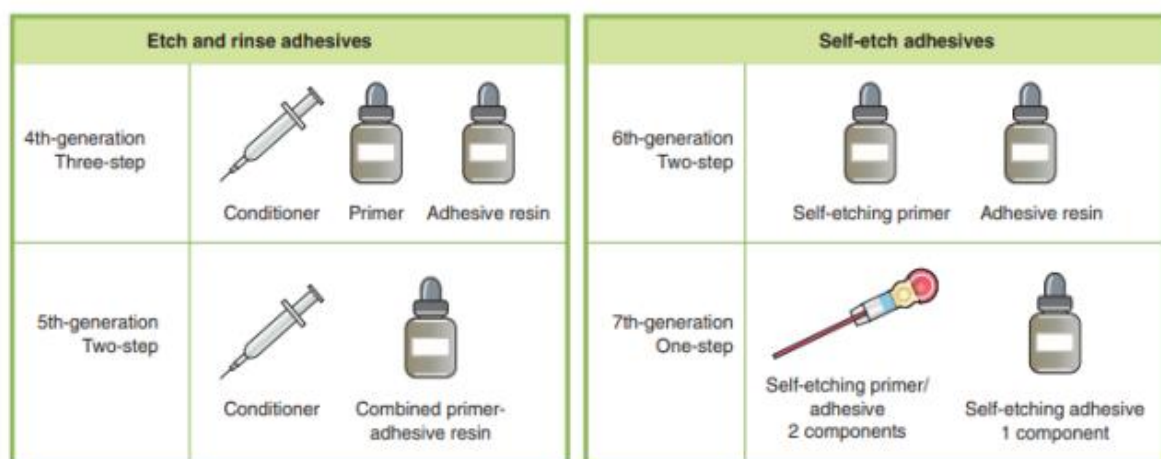
### Classification of Dentin Bonding Agents

#### 1. By Generations:<sup>8-11</sup>

A tabulated difference comparison between the various generations has been described in the Table no. 1

Generation	Key Characteristics	Composition	Mechanism of Action	Limitations
First Generation e.g., Cervident	Initial adhesive dentistry systems	Glycerophosphoric acid dimethacrylate (NPG-GMA)	Micromechanical retention; ionic and covalent bonding	High polymerization shrinkage, high thermal expansion, poor durability, sensitive to water

<b>Second Generation</b> e.g., ScotchBond	Introduction of hybrid layer	Polymerizable phosphates, bis-GMA resins	Micromechanical and chemical adhesion; ionic bonds	Weaker bond due to smear layer, prone to degradation in water
<b>Third Generation</b>	Etch-and-rinse technique introduced	Hydrophilic and hydrophobic monomers	Micromechanical retention and chemical bonding	Weak link with unfilled resins, sensitivity in etching dentin
<b>Fourth Generation</b> eg: Optibond FL	Total-etch technique, gold standard	Advanced adhesive monomers, hydrophilic and hydrophobic monomers	Micromechanical interlock and chemical bond	Technique-sensitive, multiple steps, complex application
<b>Fifth Generation</b> E.g., Adper Single Bond 2(3M, ESPE)	Simplified application, one-bottle system	Combined primer and adhesive, advanced monomers	Micromechanical retention and chemical bonding	More susceptible to water degradation, not always compatible with dual/self-cured materials
<b>Sixth Generation</b> e.g., Clearfil SE Bond, (Kuraray dental)	Self-etch systems, reduced steps	Acidic monomer for conditioning and priming	One-step self-etch, no rinsing	
<b>Seventh Generation</b> e.g., iBond (kerr).	Single-step, self-etch systems	Combined conditioner, primer, bonding resin	No separate etching step	High water content, prone to hydrolysis, limited long-term data
<b>Eighth Generation</b> e.g., Scotchbond Universal Plus (3M ESPE)	Incorporation of nanosized fillers	Polyfunctional adhesive monomers, SiO <sub>2</sub> nanoparticles	Improved resin penetration, thicker hybrid layer	High viscosity with larger nano-fillers, potential for flaws



**Figure 2:** Classification of current adhesive systems according to van Meerbeek et al. 2003. (Figure adapted from Cardoso MV, de Almeida Neves A, Mine A, et al: Current aspects on bonding effectiveness and stability in adhesive dentistry. Aust Dent J 56(S1):31–44, 2011.)<sup>12</sup>

**2. By Procedural Steps:**<sup>13</sup>

- Three-step systems (etching, priming, bonding) e.g., Scotchbond Multipurpose (3M ESPE)
- One-step self-etch adhesives e.g., Xeno V (Dentsply Sirona).

**Hanabusa et al (2012)**<sup>14</sup> evaluated if a new one-step adhesive could be applied in a multi-mode manner, either 'full' or 'selective', self-etch and etch-and-rinse approaches and concluded that the bonding effectiveness of the one-step self-etch adhesive could be improved by etching the enamel margins selectively with phosphoric acid.

**3. By Etching Pattern:**<sup>15</sup>

- Total-etch systems (fourth and fifth generations) e.g., Adper Single Bond 2.
- Self-etch systems (sixth and seventh generations) e.g., Scotchbond Universal Plus.

**4. By pH Levels:**<sup>16</sup>

- Strong (pH 1) e.g., Tyrian SPE,
- mild (pH 2) e.g., Clearfil SE Bond,
- intermediate (pH 1.5) e.g., OptiBond All-In-One self-etch adhesives.

**Ahn et al (2015)**<sup>17</sup> concluded that the effect of additional acid etching on the dentin bond strength was influenced by the pH of one-step self-etch adhesives. Ethanol wetting on etched dentin could create a stronger bonding performance of one-step self-etch adhesives for acid etched dentin.

**Composition of Dentin Bonding Agents**

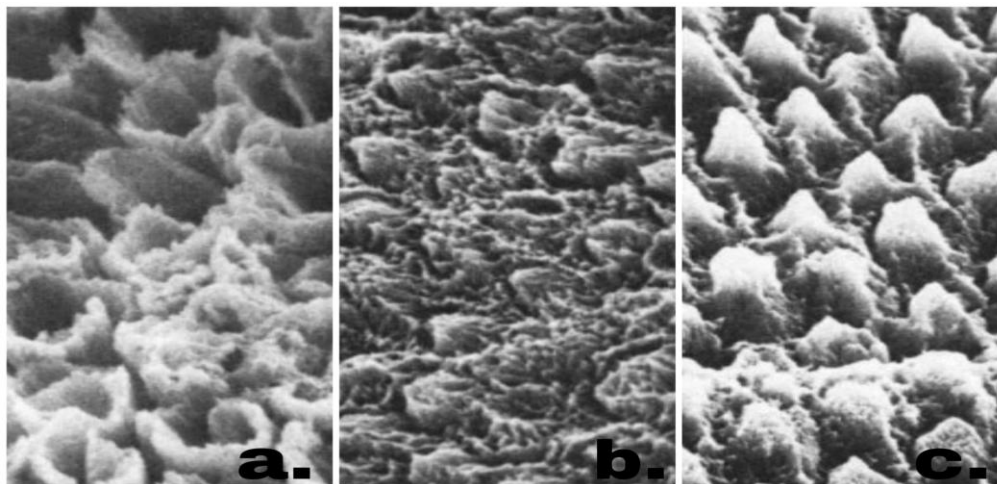
Dentin bonding agents consist of various key components.<sup>18</sup>

Following is a detailed table summarizing the composition of dentin bonding agents:

Component	Type	Description	Function
<b>Etchants</b>	Strong Acids	Typically phosphoric acid (30-50%, usually around 37%).	Removes smear layers and dissolves the mineral phase to facilitate micromechanical interlocking.
<b>Primers</b>	Solutions	Contain hydrophilic monomers (e.g., HEMA) dissolved in solvents (water, ethanol, acetone).	Keeps the collagen network expanded, allowing hydrophobic adhesive monomer infiltration.
<b>Adhesives</b>	Resin Compositions	Mainly hydrophobic dimethacrylates (e.g., bis-GMA, TEGDMA, UDMA) with some hydrophilic monomers (HEMA).	Fills the interfibrillar space, creating a hybrid layer and resin tags for micromechanical retention.
<b>Initiators</b>	Chemical Agents	Includes photoinitiators (e.g., camphorquinone), self-cure systems (e.g., benzoyl peroxide), and dual-cure systems.	Initiate the polymerization process of adhesives and restorative composites.
<b>Filler Particles</b>	Nanoparticles	Nanometer-sized silica particles added to some adhesives.	Reinforce adhesives, increase bond strength, and modify viscosity.
<b>Other Ingredients</b>	Additives	Includes glutaraldehyde (desensitizer), MDPB and parabene (antimicrobials), fluoride (prevents caries), and chlorhexidine (prevents collagen degradation).	Enhance effectiveness and longevity of bonding agents.

Patterns of etching:<sup>19</sup>

<b>Type 1</b>	Most common etching pattern. This involves removal of enamel prism cores with prism peripheries remaining leaving intact
<b>Type 2</b>	Here peripheries are removed leaving the cores intact
<b>Type 3</b>	This is associated with the presence of prism less enamel



**Figure 1. :** a. type 1 etching pattern, b. type 2 etching pattern, c. type 3 etching pattern  
**Source:** Galil, K.A. and Wright, G.Z., 1979. Acid etching patterns on buccal surfaces of permanent teeth. *Pediatr Dent*, 1(4), pp.230-4.

#### **Bonding to Hydroxyapatite:** <sup>20</sup>

The formula M-R-X) shows the chemical bonding in dentistry.

M - Stands for the methyl methacrylate group including the -CO-O- bond).

R - stands for a spacer consisting of a hydrocarbon chain,

X - is the group capable of bonding to calcium present on the tooth surface.

#### **The Smear Layer In Dentin Bonding**

**Pashley et al (1981)**<sup>21</sup> observed that the removal of the smear layer allowed for increased fluid filtration across dentin, emphasizing its role as a barrier to convective transport. The smear layer, formed during tooth preparation, consists of dentin debris, hydroxyapatite, and collagen. It blocks dentinal tubules, reducing permeability and adhesive penetration, but can be modified or removed using agents like sodium hypochlorite, EDTA, or phosphoric acid to enhance adhesion and bond strength (**Goldman et al. (1981)**).<sup>22</sup>

#### **The Hybrid Layer in Dentin Bonding**

The hybrid layer, first described by **Nakabayashi et al. (1991)**<sup>23</sup>, is a resin-dentin interface essential for durable bonding. It consists of demineralized collagen and infiltrated resin, forming a mechanical and chemical bond that enhances resistance to microleakage. However, it is prone to degradation from hydrolysis, incomplete resin infiltration, and enzymatic activity (e.g., MMPs, CTs). Strategies

such as cross-linking agents and optimized adhesive formulations help stabilize the hybrid layer. **Frassetto et al (2015)**<sup>24</sup> stated that inhibiting collagenolytic activity and employing cross-linking agents are two primary strategies To enhance the resistance of the hybrid layer to enzymatic degradation.

#### **Enamel and Dentin Adhesion**

Enamel adhesion relies on acid etching to create microtags within the enamel, significantly enhancing bond strength, often exceeding 20 MPa. Shorter etching times have proven effective in maintaining bond efficacy while reducing the risk of complications. Dentin adhesion, however, is more complex due to its moisture-sensitive nature. It involves resin infiltration into the collagen network, forming a hybrid layer essential for strong, durable bonds. **Perdigão (2010)** discussed the variables related to clinical situation and substrate treatment in dentin bonding. The author identified crucial factors—wetness of dentin, pulpal pressure, and

dentin thickness— influencing bonding procedures. **Malacarne et al (2006)**<sup>25</sup> evaluated the water sorption, solubility and kinetics of water diffusion in commercial and experimental resins that are formulated to be used as dentin bonding agents and concluded that extensive water sorption affected the mechanical stability and lead to potential dentin bond degradation. Proper moisture control and precise etching protocols are critical for optimizing adhesion.

### **Recent Advances in Dentin Bonding Agents**

Recent advancements in adhesive dentistry have focused on improving both performance and longevity. Functional monomers have enhanced hybrid layer stability, while protease inhibitors have been introduced to prevent collagen degradation. ER:YAG lasers have emerged as a valuable tool for removing the smear layer and creating micro-retentive features, improving bond strength. The incorporation of nanoparticles has further reinforced bonding agents, promoting remineralization and enhancing durability. Universal adhesives have simplified the bonding process, with crosslinkers offering additional improvements in performance.<sup>26</sup> **Mahmoud (2023)**<sup>27</sup> discussed the various strategies for improving the performance of dental adhesive systems incorporating anti-MMP and collagen crosslinking agents, bioactive glass for

remineralization, and antibacterial agents such as Quaternary Ammonium Salts (QAS), MDPB monomer, and Benzalkonium chloride. Looking ahead, future developments in adhesive dentistry include biomimetic adhesives, self-repairing systems, fluorescent markers for detecting marginal leakage, and the integration of digital technologies for creating custom bonding solutions.

### **CONCLUSION**

Dentin bonding agents have undergone remarkable evolution, transforming restorative dentistry with advancements that address critical challenges like bond strength, durability, and tooth structure preservation. From the early generations focused primarily on enamel bonding to the latest bioactive and biomimetic adhesives, these agents have consistently pushed the boundaries of dental science and clinical efficacy. Looking ahead, the future of dentin bonding agents lies in the exploration of bioactive materials and biomimetic strategies that closely mimic natural tooth structures while promoting remineralization and tissue preservation. As research and technology continue to progress, these cutting-edge adhesives will revolutionize restorative dentistry, ensuring better outcomes for patients and enabling dental professionals to deliver care that is both highly effective and minimally invasive.

## **BIBLIOGRAPHY**

1. Van Meerbeek B, De Munck J, Yoshida Y, Inoue S, Vargas M, Vijay P, Van Landuyt K, Lambrechts P VGB. Adhesion to enamel and dentin: current status and future challenges. *Oper Dent*. 2003;28:215–35.
2. Van Nieuwenhuysen JP, D’Hoore W, Carvalho J, Qvist V. Longterm evaluation of extensive restorations in permanent teeth. *J Dent* 2003; 31: 395-405 (Pub Med: 12878022).
3. Abedin F, Ye Q, Parthasarathy R, Misra a., Spencer P. Polymerization Behavior of Hydrophilic-Rich Phase of Dentin Adhesive. *J Dent Res* [Internet]. 2015;94(3):500–7. Available from: <http://jdr.sagepub.com/cgi/doi/10.1177/0022034514565646YiuC>
4. Söderholm, KJ, 2007 ‘Dental adhesives... how it all started and later evolved’, *Journal of Adhesive Dentistry*, vol. 9, no. 2, pp.227-30.
5. Nelsen, RJ, Wolcott, RB & Paffenbarger, GC, 1952 ‘Fluid exchange at the margins of dental restorations’, *Journal of the American Dental Association*, vol. 44, no. 3, pp. 288-95.
6. Rose, EE, Lai, J, Williams, NB & Falcetti, JP, 1954 ‘The screening of materials for adhesion to human tooth structure’, *Journal of Dental Research*, vol. 34, no.4, pp. 577-88
7. Buonocore, MG, 1955 ‘A simple method of increasing the adhesion of acrylic filling materials to enamel surfaces’, *Journal of Dental Research*, vol. 34, no. 6, pp. 849-53
8. Anusavice, KJ, 2003 ‘Phillips’ Science of Dental Materials (2nd ed.)’, Elsevier.
9. Roberson, TM, 2002 ‘Sturdevant’s Art and Science of Operative Dentistry (4th ed.)’, Mosby, pp. 237-367.

10. Kakar, S and Kanase, A, 2013 'Dentin bonding agents I: complete classification—a review', *World Journal of Dentistry*, 2, pp.367-370.
11. Farah, JW and Powers, JM, 2004 'The Dental Advisor, 21 'The Dental Advisor', June 2008, vol. 25, no. 05. 111. Kugel, G and Ferrari, M, 2007 'The science of bonding: from first to sixth generation', *Journal of the American Dental Association*, pp.1-4
12. Cardoso, M.V., de Almeida Neves, A., Mine, A., Coutinho, E., Van Landuyt, K., De Munck, J. and Van Meerbeek, B., 2011. Current aspects on bonding effectiveness and stability in adhesive dentistry. *Australian dental journal*, 56, pp.31-44.
13. Dunn, JR, 2003 'iBond: The seventh generation, one-bottle dentine bonding agent', *Compendium of Continuing Education in Dentistry*, vol. 24, pp.14-8.
14. Hanabusa, M, Mine, A, Kuboki, T, Momoi, Y, Van Ende, A, Van Meerbeek, B & De Munck, J, 2012 'Bonding effectiveness of a new 'multi-mode' adhesive to enamel and dentine', *Journal of Dentistry*, vol. 40, no. 6, pp. 475-84.
15. Perdigão, J, 2007 'New developments in dental adhesion', *Dental Clinics of North America*, vol. 51, pp. 333-57.
16. Kanheira, M, et al, 2005 'Relationship between degree of polymerization and enamel bonding strength with self-etching adhesives (all-in-one or 7th-generation)', *Journal of Adhesive Dentistry*, vol. 7, pp.300-5.
17. Ahn, J, Jung, KH, Son, SA, Hur, B, Kwon, YH & Park, JK, 2015 'Effect of additional etching and ethanol-wet bonding on the dentin bond strength of one-step self-etch adhesives', *Restorative Dentistry & Endodontics*, vol. 40, no. 1, pp. 68-74.
18. Fusayama T, Nakamura M, Kurosaki M, et al 1979 'Nonpressure adhesion of a new adhesive restorative resin'. *J Dent Res*, vol. 58, pp. 1364,
19. Galil, K.A. and Wright, G.Z., 1979. Acid etching patterns on buccal surfaces of permanent teeth. *Pediatr Dent*, 1(4), pp.230-4.
20. Anusavice, KJ, Shen, C and Rawls, HR eds, 2012 *Phillips' science of dental materials*, Elsevier Health Sciences.
21. Pashley, DH, Michelich, V, & Kehl, T, 1981, 'Dentin permeability: effects of smear layer removal', *The Journal of Prosthetic Dentistry*, vol. 46, no. 5, pp. 531-37.
22. Goldman, LB, Goldman, M, Kronman, JH & Lin, PS, 1981 'The efficacy of several irrigating solutions for endodontics: a scanning electron microscopic study', *Oral Surgery, Oral Medicine and Oral Pathology*, vol. 52, pp. 197-204.
23. Nakabayashi, N, Nakamura, M & Yasuda, N, 1991 'Hybrid layer as a dentin-bonding mechanism', *Journal of Esthetic Dentistry*, vol. 3, pp.133-8.
24. Frassetto, A, Breschi, L, Turco, G, Marchesi, G, Di Lenarda, R, Tay, FR, Pashley, DH & Cadenaro, M, 2016 'Mechanisms of degradation of the hybrid layer in adhesive dentistry and therapeutic agents to improve bond durability—A literature review', *Dental Materials*, vol. 32, no.2, pp. e41-53.
25. Malacarne, J, Carvalho, RM, de Goes, MF et al, 2006 'Water sorption/solubility of dental adhesive resins', *Dental Materials*, vol. 22, no. 10, pp. 973-80.
26. Shah, P, Panjeta, TK, Mahla, N, Khan, ZS & Deshmukh, GF, 'Current advances in adhesive dentistry: a mini review'.
27. Mahmoud, YS, 2023 'Recent advances in contemporary dental adhesives', *Biomaterials Journal*, vol. 2, no. 3, pp. 40-55.

# Comparison of Marginal and Internal Fit of Metal Copings Fabricated by Cad/Cam Milling, Cad/Cam Wax and Conventional Lost Wax Technique

Dr. Vineeta Tailor,<sup>1</sup> Dr. Meenakshi Khandelwal,<sup>2</sup> Dr. Deepak Mahla,<sup>3</sup> Dr. Abhishek Bhartiya,<sup>4</sup> Dr. Neeraj Yadav<sup>5</sup> Dr. Rajeev Soangra<sup>6</sup>

- 1. Dr. Vineeta Tailor**  
PG Student, Department of Prosthodontics and Crown & Bridge and Oral Implantology, Rajasthan Dental College & Hospital, Jaipur, Rajasthan, India.
- 2. Dr. Meenakshi Khandelwal**  
Professor and Head of the Department, Department Of Prosthodontics and Crown & Bridge and Oral Implantology, Rajasthan Dental College & Hospital, Jaipur, Rajasthan, India.
- 3. Dr. Deepak Mahla**  
Professor, Department of Prosthodontics and Crown & Bridge and Oral Implantology, Rajasthan Dental College & Hospital, Jaipur, Rajasthan, India.
- 4. Dr. Abhishek Bhartiya**  
Reader, Department of Prosthodontics and Crown & Bridge and Oral Implantology, Rajasthan Dental College & Hospital, Jaipur, Rajasthan, India.
- 5. Dr. Neeraj Yadav**  
Reader, Department of Prosthodontics and Crown & Bridge and Oral Implantology, Rajasthan Dental College & Hospital, Jaipur, Rajasthan, India.
- 6. Dr. Rajeev Soangra**, Assistant Professor, Department of Periodontology, RUHS College of Dental Science, Jaipur, Rajasthan, India.

## CORRESPONDING AUTHOR

**Dr. Rajeev Soangra,**

Assistant Professor, Department of Periodontology,  
RUHS College of Dental Science,  
Jaipur, Rajasthan, India.

**Mobile** - rajeevsoangra@gmail.com

**Email** - 7737323235

## Abstract

**Background:** In dentistry, metal ceramic prostheses are still frequently used despite the advent of metal-free prostheses. Because the marginal and internal fit of metal copings milled directly by CAD/CAM and cast from wax patterns created by CAD/CAM and conventional lost wax process are critical to the clinical outcome of a restoration, this study aimed to assess and compare these parameters.

**Materials and Methods:** PFM crown preparation with chamfer margin was performed on a maxillary first molar typodont tooth. The impression material used for the master models impression was elastomeric material. .30 dies were obtained and randomly divided into three group of 10 dies for each group(n = 10). Group A Copings fabricated by Conventional lost wax pattern, Group B Copings fabricated by CAD/CAM milling and Group C Copings fabricated by CAD/CAM wax pattern milling and conventional casting.. Along with longitudinal sectioning, each coping was cemented onto its corresponding die. A 100x optical microscope was used to measure the internal and marginal gaps at seven different places.



**Results** Data analysis was done using a one-way ANOVA with Tukey HSD pair-wise comparisons. Groups A, B, and C had mean overall gaps of  $168.53 \pm 37.26 \mu\text{m}$ ,  $109.62 \pm 24.96 \mu\text{m}$ , and  $47.49 \pm 14.99 \mu\text{m}$ , respectively. Group B and Group C had the next greatest internal and marginal gaps, respectively. Group A displayed the largest gaps. The groups differed in both internal and marginal fit in a statistically significant way.

**Conclusion:** In comparison to CAD/CAM and traditional lost wax technique, metal copings made from wax patterns created using CAD/CAM and conventional casting technique had smaller marginal and internal gap.

**Keyword:** Marginal fit, Internal fit, PFM, FPD, CAD/CAM, STLfile

## INTRODUCTION

The main objective of fixed prosthodontics treatment is the replacement and restoration of teeth using artificial substitutes. This might encompass anything from the rehabilitation of a full occlusion to the repair of a single tooth.<sup>1</sup> Materials used to fabricate prostheses in modern fixed prosthodontics include all metal, porcelain fused to metal, and all ceramic.<sup>2</sup> Because of its exceptional mechanical qualities, acceptable aesthetics, affordable price, and simple cementation process, porcelain fused to metal prostheses remain one of the most popular materials for the fabrication of fixed partial dentures. A metal framework or coping is covered in multiple layers of sintered porcelain material is used to create a porcelain fused to metal prosthesis.

Metal coping can be made using the conventional lost wax process, CAD/CAM milling, and CAD/CAM wax pattern followed by traditional casting.<sup>3</sup> The lost wax technique, which was developed by Taggart in the early 1900s, makes it possible to fabricate crowns, inlays, onlays, and FPDs.<sup>4</sup> Wax and waxing tools were used to create wax pattern fabrication in the past. Wax is used to create the patterns because it is easily worked, can be moulded exactly, and can be heated to remove it entirely from the mould.<sup>4</sup> The crucial and labour-intensive phase in creating the porcelain fused-metal coping is making the wax pattern. Computer-aided design/computer-aided manufacturing (CAD/CAM) technologies have been established in an attempt to solve the drawbacks of the traditional lost-wax process.<sup>5</sup> When it comes to flow characteristics, shrinkage, and expansion during heating and cooling, CAD/CAM wax differs from Inlay wax.

CAD/CAM wax which is made from a polymerisation reaction, is a solid synthetic wax that is less susceptible to temperature changes.<sup>6</sup>

Nowadays CAD/CAM technology, which has turned into a significant revolution, being able to create incredibly exact designs and high-quality restorations makes it an advancement over conventional dentistry. Unfortunately, the expense and duration of the process are also limited by scanning systems' finite resolution, which may lead to somewhat rounded edges; other limitation include equipment's wear and tear.<sup>7</sup>

The biological, physical, and aesthetic criteria of restorations must be fully satisfied by precise marginal seating and internal fit of cast restorations. The precision and fine detail of the wax pattern will play a major role in the casting's fit and quality.<sup>8</sup> Inadequate coping internal adaptation can lead to increased cement thickness and water sorption, which degrades cements hydrolytically and lowers their elastic modulus, which in turn lowers the mechanical durability of dental restorations. A too thick layer of cementitious material can lead to periodontal inflammation, cavities, and ultimately the restoration's loss.

Therefore, the current study was taken to assess and compare the marginal and internal fit of metal coping milled directly by CAD/CAM and cast from wax pattern fabricated by CAD/CAM and conventional lost wax technique.<sup>9</sup>

## MATERIAL AND METHODS

This invitro study was carried out in Department of Prosthodontics and Crown & Bridge and Oral Implantology Rajasthan Dental College & Hospital, Jaipur, Rajasthan.

### Methodology:

#### Fabrication of Master Model

To replicate full coverage PFM crown preparation, a maxillary first molar typodont tooth was prepared with a chamfer margin around the entire circumference, occlusal clearance of 1.5

mm for nonfunctional cusp, 2 mm for functional cusp, and 1.5 mm for axial reduction. The preparation features a 0.7 mm chamfer width and a 6-degree convergence angle.

### **Fabrication of Die Specimens**

Custom fabricated, self-cure acrylic resin impression trays were made in order to take

impressions of the master model. Using a single-stage method, impressions of the master model were made using C-silicone impression material (orikam). To create the die stone models, 30 impressions were taken and type IV die stone (kalabhai kalrock) was poured. (Figure 1)



**Fig 1 Dies prepared and randomly allotted to three groups**

**30 dies were obtained and randomly divided into three groups of 10 dies for each group (n=10)**

- **Group A:** Copings fabricated by conventional lost wax pattern.
- **Group B:** Copings fabricated by CAD/CAM milling.
- **Group C:** Copings fabricated by CAD/CAM wax pattern milling and conventional casting.

### **Fabrication of Group A Specimens (conventional lost wax pattern)**

A coat of die spacer was applied 1mm away from the margin, each layer of die spacer (DFS india) has a thickness of 20µm. After drying, a thin layer of separating medium (Renfert) was applied to the dies to remove the wax pattern easily. Wax pattern was fabricated by addition wax technique by type

2 inlay wax (JK industries). Wax was added and shaped by PKT instruments to form and follow the emergence profile of die. The thickness of the copings was confirmed with a thickness gauge to be 0.6mm. Finally, to readaptation of the margin was done. Prefabricated Wax sprues were attached, and all wax patterns were invested in a phosphate bonded investment (Begosol). After heating to 950°C for wax elimination the copings were cast in Ni- Cr Alloy (Agkem Impex) using a casting machine (Bego Fornax T). The castings A1 to A10 according to their wax pattern code were removed from the investment and cleaned with aluminium oxide particles. The casting sprues were removed by using a polisher and grinder machine with a separating disc, after finishing and polishing 10 metal coping were fabricated. (Fig 2)




**Fig 2: Group A metal copings**

**Fabrication of Group B Specimens (CAD/CAM Milling)**

For the fabrication of CAD/CAM milled copings, ten dies were used. A 3D scanner (Lianoning Upcera) was utilised to scan the dies. The CAD program (CAD Design software) received the scanned data and used it to create patterns with a thickness of 0.6

mm and a cement space of 20 µm for the axial and occlusal surfaces and no cement space at the border. An STL file, or standard tessellation language, was the product of this. The milling machine received the design and used it to construct frameworks out of the metal blank. Following coping milling, it was separated from the remaining disc. (Fig3)

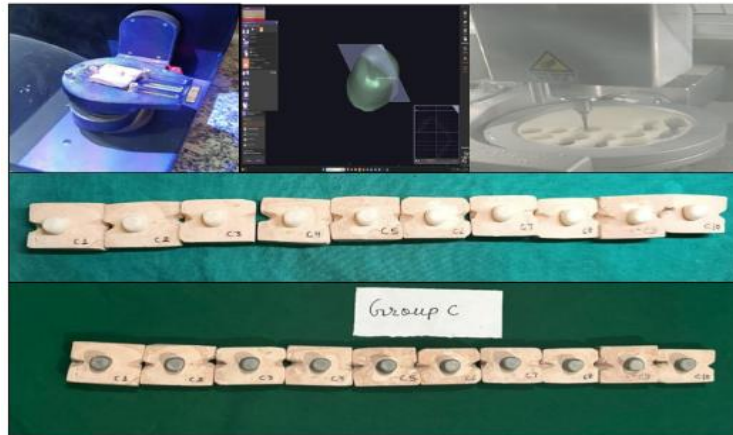


**Fig 3: Group B metal copings**

**Fabrication of Group C Specimens (CAD /CAM Wax Pattern Fabrication and Conventional Casting)**

10 Dies were used to fabricate the CAD/CAM wax pattern. Dies were scanned by using a scanner (Lianoning Upcera). The scanning data were transferred to the CAD software (CAD Design software), in which the thickness of the patterns was set at 0.6 mm, and a cement space of 20 µm was considered for the occlusal and axial surfaces, with no cement space at the margin. The output of this design was a standard tessellation language (STL) file. The design was sent to the milling machine

(Cradle Medical) and frameworks were fabricated from the wax blank (Tuskerdent) with milling machine. After the milling of wax pattern was done it was separated from the remaining of the disc. Prefabricated Wax sprues were attached, and all wax patterns were invested in a phosphate-bonded investment. After heating to 950°C for wax elimination the copings, were casted in Ni- Cr Alloy using a casting machine. The castings C1 to C10 according to their wax pattern were removed from the investment and cleaned. The casting sprues were removed after finishing and polishing of metal copings was done. (Fig 4).




**Fig 4 : Group C metal copings**

**Cementation of Test Specimen**

Glass-ionomer cement was used to firmly cement copings to their corresponding die specimens. A suitable mixture of powder and liquid was prepared

for GIC (Shofu Inc., Tokyo). A gauze pad was used to remove the extra cement. The finger-pressured seating force is used to mimic a clinical situations. (Fig 5)




**Fig 5: Cementation of test specimens**

**Sectioning Of Specimens**

Using a carborundum disc in a die cutting machine(Unident), the specimens were sectioned.

After being fixed, each specimen was sectioned into two halves. Specimens were fine-finished and cleaned to get rid of any debris. (Fig 6)

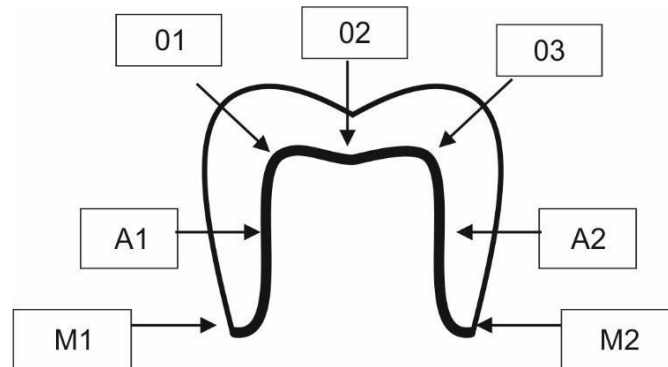


**Fig 6: Sectioning of test specimens**

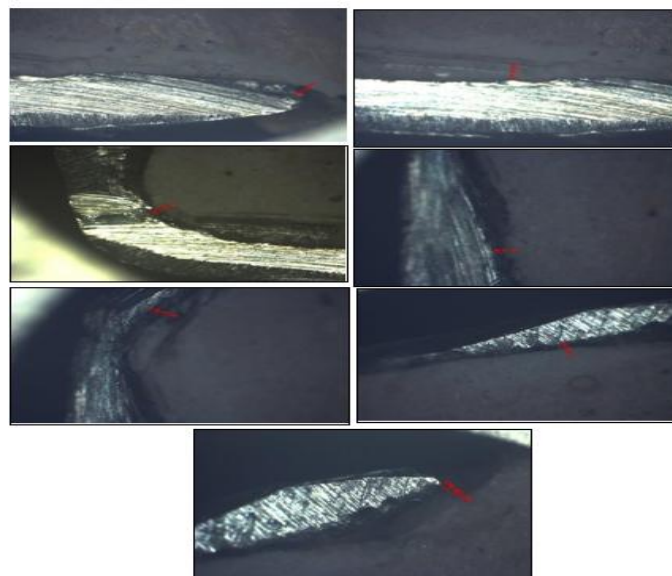
### Measurements of Marginal & Internal Fit

Following the completion of the longitudinal sectioning to determine the internal and marginal gaps. The marginal and internal fits of the metal coping were determined at seven different sites. Every

measurement was taken with a Zeiss optical microscope. Digital photos were captured at a 100x magnification and examined using a measurement tool. (Fig 7) (Fig 8)



**Fig 7: Schematic line diagram of measurement locations (M1, M2, A1, A2 and O1, O2, O3)**



**Fig 8: Measurement of marginal and internal gap of specimen's Statistical analysis**

### Statistical analysis

To do a multiple comparison between the three groups, one way analysis of variance (ANOVA) post Hoc Tukey HSD was utilised to tabulate and statistically analyse the findings for marginal and internal fit. A significant threshold of  $P \leq 0.05$  was applied.

### RESULT

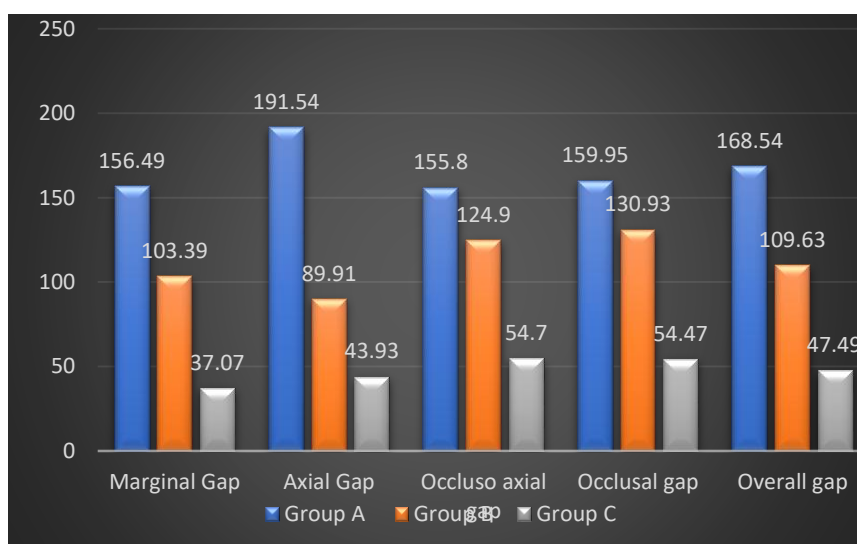
On statistical analysis it was found that there was statistically significant difference between mean marginal and internal gap among all test groups. (Table 1) (Graph 1)

**Table 1: Shows mean marginal and internal gaps of specimens of all groups**

Group	Mean Marginal Gap (in um)	Mean Axial gap (in um)	Mean Occluso axial gap( in um)	Mean Occlusal Gap( in um)	Mean overall Gap( in um)
<b>Group A</b>	156.49±42 .66 <sup>a</sup>	191.53±90 .93 <sup>a</sup>	155.83±53 .91 <sup>a</sup>	159.94±67 .72 <sup>a</sup>	168.53±37 .26
<b>Group B</b>	103±27 .99 <sup>b</sup>	89.90±27 .23 <sup>b</sup>	124.90±41 .12 <sup>b</sup>	130.96±44 .21 <sup>b</sup>	109.62±24 .96
<b>Group C</b>	37.07±11 .95 <sup>c</sup>	43.92±17 .63 <sup>c</sup>	54.78±17. 65 <sup>c</sup>	54.47±29 .47 <sup>c</sup>	47.49±14 .99

Same lowercase superscript letters denote values not significantly different among same column

**Graph 1: Shows mean marginal and internal gaps of specimens of all groups**



## DISCUSSION

Methods for fabricating metal copings include the conventional lost wax process, CAD/CAM metal coping fabrication, and CAD/CAM wax pattern fabrication followed by traditional casting. This study was conducted to compare the marginal and internal fit of metal copings milled directly by CAD/CAM and cast from wax pattern fabrication by CAD/CAM and conventional lost wax technique. Marginal errors may cause plaque to be retained, which can result in gingival recession, marginal gingival irritation, and the formation of secondary caries behind the crown edges. One possible reason for the failure could be marginal inaccuracy. This study uses tooth analogues made of acrylic resin to replicate a clinical situation. According to a

study conducted by Hyun-Sook Han, Hong-So Yang, Hyun-Pil Lim, and Yeong-Joon Park, the coping in all three groups had to have a uniform thickness of .6mm for each wax design that was manufactured.<sup>10</sup> In order to replicate the clinical cementation of FPD, finger pressure was used to seat the crown on the die. The clinical scenarios were not simulated in this investigation using a standardised force, as in the study by Anders Ortorpa, David Jonsson, Alaa Mouhsen, and Per Vult von Steyern.<sup>11</sup> The CAD/CAM procedures were standardised by using the same scanner, and the casting technique was optimised for melting by using an induction casting machine. The lost wax process involves making manual wax patterns, which are sensitive to technique. In order to reduce these concerns, the

waxing and casting were done by the same operator.<sup>12</sup> The longitudinal cross-sectional methodology was used in this study to verify the marginal and internal fit. This method requires the sacrifice of a sample, but the results are more precise since the measurement sites are more precise and consistent.<sup>13</sup>

The variation in the pattern of wax distortion between the CAD/CAM and manual wax could account for the disparity in adjustment interventions between the two groups (group A and group C). The hand-fabricated wax's flow characteristics, shrinkage, and expansion following uneven heating and cooling are the primary causes of these variations, whereas the solid synthetic wax utilised in CAD/CAM is made through a polymerisation reaction and is less temperature-sensitive.<sup>14</sup> When compared to the inlay wax utilised in the traditional lost wax method, the marginal gap of the crown manufactured using CAD/CAM wax was noticeably less. This outcome could be the result of minor flaws in the hand waxing process brought on by the glossy surface and colour of the wax pattern. Such outcomes are also influenced by the typical 35-um opening of the shoulder margin prior to investing that occurs during the process of extracting a wax pattern from a die.<sup>15</sup>

Result of this study showed all values for marginal and internal fit for Group B and Group C were found in the range of clinical acceptance, while for the conventional technique (Group A) were higher than the accepted value of 120 um and statistically significant result were obtained for Group A (copings fabricated by conventional wax pattern and casting), Group B (copings fabricated by CAD/CAM milling) and Group C (copings fabricated by CAD/CAM wax pattern milling and conventional casting). Group C showed better marginal and internal fit followed by Group B and Group A.

Group C is a combination of old and new techniques. In comparison with the traditional lost wax technique group A, it presented the less amount of measurement distortion values. However, the group A had higher value, one explanation for the larger distortion in the lost wax group could be that the spacer is difficult to standardize, and distortion could be set when the wax is removed from the

model. The CAD/CAM technique contains fewer production steps compared to the lost technique. The group B had higher distortion values than group C this could be explained by wear of the milling burs when milling such a hard material as Ni-Cr. Therefore, the burs must be changed often to reduce the risk of using burs with decreased diameters. Vibrations in the milling device could also be a reason for the results in the group. There were some limitations in this study.

There were some limitations in this study.

- The force used to seat the restorations was not standardized. The use of a loading apparatus would provide a more uniform load on all the specimens.
- The marginal accuracy measures in this study were based on the simulation of tooth configurations ready to receive full crowns using stone dies. To simulate a clinical process, human teeth would be the best option.
- In this study the measurement area is restricted to the sectioned line so only provide a 2D information.
- Present study was done in vitro conditions result can vary in oral environment.
- Small specimen size.

#### **CLINICAL CONSIDERATION**

Metal coping created by CAD/CAM wax and conventional casting exhibited superior marginal fit and internal fit than CAD/CAM milling and conventional casting, thus it can be recommended for metal coping fabrication even though the CAD/CAM technique's values were within clinically acceptable bounds. Because of its improved marginal and internal fit, it influences the restoration's clinical outcome. Less plaque buildup, marginal gingival irritation, gingival recession, and cavities are all benefits of improved marginal fit.

#### **SCOPE FOR FUTURE RESEARCH**

- Effect of veneering ceramic application on the marginal and internal fit of metal coping.
- Measurement of mechanical properties and metal to ceramic bond strength and to assess the 3D volume between metal coping and dies.
- Study can be done in vivo to simulate the oral environment

## CONCLUSION

With the limitations of this study, the following conclusions could be derived as

➤ Metal copings fabricated by CAD/CAM wax showed better marginal and internal fit than manual wax.

Result for marginal and internal fit of this study was statistically significant and showed that mean

marginal fit for Group C (metal copings fabricated from wax pattern fabricated by CAD/CAM and conventional casting technique) exhibited maximum marginal and internal fit followed by Group B (metal copings fabricated by CAD/CAM) and Group A (metal copings fabricated from conventional lost wax technique).

## BIBLIOGRAPHY

1. Kalsekar BG, Gandhi PV, Patil R, Sabane AV, Kadam PP, Bhosale NS. Comparative evaluation of retention and vertical marginal accuracy of co-cr copings fabricated using three different techniques: an in vitro study. *The Journal of Contemporary Dental Practice*. 2022 Oct 1;23(10):992.
2. Lee KB, Park CW, Kim KH, Kwon TY. Marginal and internal fit of all-ceramic crowns fabricated with two different CAD/CAM systems. *Dental materials journal*. 2008;27(3):422-6
3. Ullattuthodi S, Cherian KP, Anandkumar R, Nambiar MS. Marginal and internal fit of cobalt-chromium copings fabricated using the conventional and the direct metal laser sintering techniques: A comparative: in vitro: study. *The Journal of Indian Prosthodontic Society*. 2017 Oct 1;17(4):373- 80.
4. Ammar A, Eanas I, Amer S. Marginal discrepancy of cobalt chromium metal copings fabricated with three different techniques. *J Am Sci*. 2015;11(5):105-.
5. Vojdani M, Torabi K, Atashkar B, Heidari H, Ardakani MT. A comparison of the marginal and internal fit of cobalt-chromium copings fabricated by two different CAD/CAM Systems (CAD/Milling, CAD/Ceramill Sintron). *Journal of Dentistry*. 2016 Dec;17(4):301
6. Pani Chnadrika Chandrasekhar, Soujanya , Ravalika KN , Siddesh Kumar and Jagadeesh Konchada (2019) CAD/CAM v/s conventional technique for better marginal fit of metal copings from wax patterns. *Int. j. Adv. Res.*(2019) 7 (8),160-166
7. Shamseddine L, Mortada R, Rifai K, Chidiac JJ. Marginal and internal fit of pressed ceramic crowns made from conventional and computer-aided design and computer-aided manufacturing wax patterns: An in vitro comparison. *The Journal of prosthetic dentistry*. 2016 Aug 1;116(2):242-8.
8. Bhasin R, Suganna M, Kumar M, Gupta S, Bhargava A, Kaul S. To evaluate and compare the vertical marginal fit of metal copings fabricated from free hand wax patterns and milled wax patterns using conventional casting technique with CAD milled copings-An in vitro study. *Journal of Advanced Medical and Dental Sciences Research*. 2019 Jul 1;7(7):178-82.
9. Witkowski S, Komine F, Gerds T. Marginal accuracy of titanium copings fabricated by casting and CAD/CAM techniques. *The Journal of prosthetic dentistry*. 2006 Jul 1;96(1):47-52.
10. Han HS, Yang HS, Lim HP, Park YJ. Marginal accuracy and internal fit of machine-milled and cast titanium crowns. *The Journal of Prosthetic Dentistry*. 2011 Sep 1;106(3):191-7.
11. Ortorp A, Jonsson D, Mouhsen A, Vult von Steyern P. The fit of cobalt-chromium three-unit fixed dental prostheses fabricated with four different techniques: a comparative in vitro study. *Dent Mater*. 2011 Apr;27(4):356-63
12. Ammar A, Eanas I, Amer S. Marginal discrepancy of cobalt chromium metal copings fabricated with three different techniques. *J Am Sci*. 2015;11(5):105
13. Nawafleh NA, Mack F, Evans J, Mackay J, Hatamleh MM. Accuracy and reliability of methods to measure marginal adaptation of crowns and FDPs: a literature review. *Journal of Prosthodontics*. 2013 Jul;22(5):419-28.
14. Suarez MJ, Lozano JF, Salido MP, Martínez F. Marginal fit of titanium metal-ceramic crowns. *International Journal of Prosthodontics*. 2005 Sep 1;18(5).
15. Lee KB, Park CW, Kim KH, Kwon TY. Marginal and internal fit of all-ceramic crowns fabricated with two different CAD/CAM systems. *Dental materials journal*. 2008;27(3):422-6.



# Management of Introral Low-Flow Vascular Malformations By Intralesional Injection of Bleomycin In Paediatric Patient: A Case Report

Dr. Amit Rawat, <sup>1</sup> Dr. Mansi Lalwani, <sup>2</sup> Dr. Bhavuk Vanza, <sup>3</sup> Dr. Deepteash Ghosh <sup>4</sup>

**1. Dr. Amit Rawat**

Associate Professor, Department of Oral and Maxillofacial Surgery, Government college of Dentistry, Indore, Madhya pradesh, India

**2. Dr. Mansi Lalwani**

Post-Graduate Student, Department of Oral and Maxillofacial Surgery, Government college of Dentistry, Indore, Madhya pradesh, India

**3. Dr. Bhavuk Vanza**

Lecturer, Department of Oral and Maxillofacial Surgery, Government college of Dentistry, Indore, Madhya pradesh, India

**4. Dr. Deepteash Ghosh**

Post-Graduate Student, Department of Oral and Maxillofacial Surgery, Government college of Dentistry, Indore, Madhya pradesh, India

## CORRESPONDING AUTHOR

**Dr. Mansi Lalwani**

Department of Oral and Maxillofacial Surgery,  
Government college of Dentistry, Indore,  
Madhya pradesh, India

**Mobile** - 8085509006

**Email** - mansilalwani0@gmail.com

## Abstract

Low-flow vascular malformations (LFVMs) in the oral cavity are uncommon but can present significant clinical challenges due to their risk of bleeding, functional impairment, and aesthetic concerns. In this paper we report a case of an 8-year-old child diagnosed with an intraoral LFVM involving the gingiva. The lesion was managed with intralesional injection of Bleomycin (BLM). Significant reduction in size was observed within 6 months of commencing the therapy without any local or systemic complications. BLM is a well established treatment option for peripheral vascular malformations and lymphangiomas, however current case emphasizes its efficacy in intra-oral & gingival lesions, which adds a significant value to current medical literature.

**Keywords:** Low-flow vascular malformation, intraoral, bleomycin, intralesional therapy, paediatric vascular anomalies.

## INTRODUCTION

Mulliken and Glowacki<sup>1</sup> broadly classified vascular anomalies into two groups: vascular malformations (VMs) and haemangiomas. Depending on their flow, these VMs are further divided into high-flow and low-flow VMs (LFVMs). Arteriovenous malformation, arterial malformation, and

arteriovenous fistula are examples of high flow malformations. Low-flow malformations include venous, capillary, lymphatic, and combination malformations such as venolymphatic malformations. VMs can appear anywhere on the body but are more prevalent in the cervico-facial region. Such lesions are diagnosed preferably by

FNAC after clinico-radiological evaluation and are primarily treated medicinally by sclerosing agents. During sclerotherapy procedures, ultrasound aids in distinguishing high-flow from low-flow lesions.<sup>2</sup>

Various treatment options for VMs include irradiation, laser therapy, vessel embolization, electrochemical therapy, copper needle treatment, cryotherapy, sclerotherapy, surgical excision and a combination of these.<sup>2,3</sup> Small superficial VMs respond well to laser whereas localized lesions respond better to surgical resection. Sclerotherapy serves as a good alternative for surgical excision with minimal complications and no external scarring.<sup>2</sup> Various authors have discussed the benefits and drawbacks of sclerosing agents ranging from BLM, sodium morrhuate, absolute ethanol, ethibloc, sodium tetradecyl sulphate, OK-432.<sup>3</sup> However, BLM stands out from other sclerosing agents due to its tendency to cause significantly less swelling, pain, skin necrosis, and nerve injury than other sclerosing agents for LFVM.<sup>4,5</sup>

BLM, a cytotoxic antibiotic anti-cancer drug with a sclerosing activity, has demonstrated its efficacy and safety in treating facial VMs. There had been no local or systemic complications.<sup>6</sup>

### CASE REPORT

A male child presented to our hospital with a swelling of size 1.5cmX1.2cm over left lower molar gingiva since 2 months (Fig.1). Routine hemogram and biochemical tests revealed no significant abnormalities. A color doppler ultrasound (Fig.2) showed a relatively well defined heterogenous hypoechoic lesion of approximate size 1.7X1.2cm in submucosal plane with vascularity suggestive of LFVM. Contrast enhanced MRI (Fig.3) reported

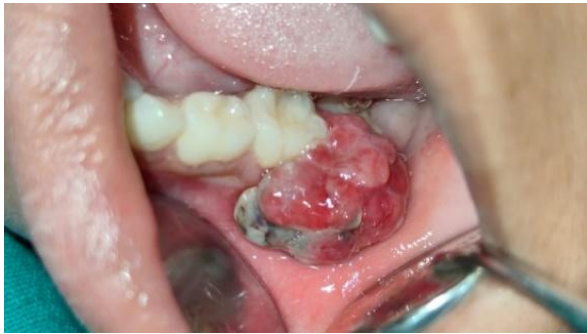evidence of heterogenous enhancing altered signal intensity lesion is seen involving left mandibular body region measuring approximately 18X15mm suggestive of VM.

Treatment plan; considering the age (8 years) and propensity of lesion was drawn to medicinal management by sclerotherapy. A written informed consent was taken before sclerotherapy explaining its treatment benefits and potential risks. BLM is available in 15 IU vials. 15 mg powdered BLM dissolved in 15 ml of 0.9% normal saline (1 IU BLM is equivalent to 1 mg/ml BLM). The safe paediatric dose of BLM is 0.5 IU/kg; with maximum dose of 15 IU/session, and at 3 weeks interval. BLM dose was calculated according to weight. Patient weighed 21kg at inception of treatment for which titrated dose was 10.5ml of BLM, given intralesionally under local anesthesia. Manual measures were done to ensure homogenous distribution of drug within the lesion at each session. Relevant observation regarding regression of lesion and local or systemic complications along with baseline parameters were documented. Dexamethasone of 2mg iv was given stat and prophylactic anti-inflammatory syrup paracetamol was administered for 3 days with dose of 100mg twice daily and then SOS. Patient's systemic was observed for 1 hour post injection of BLM, prior to discharge.

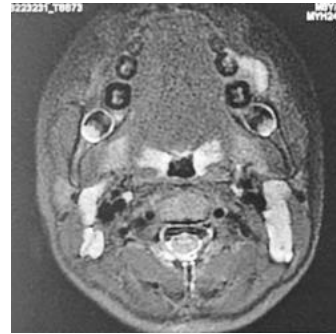Observations were made at frequency of 3 weeks interpreted as the session of BLM injections and were recorded for unbiased evaluation based on a 4-point scale that was modified by Achauer<sup>7</sup> et al. and Hassan et al.<sup>8</sup> This scale took volume, colour and texture of the lesion after treatment into consideration.

<b>1. No response</b>	no change in the size or continued to enlarge
<b>2. Mild improvement</b>	the lesions decreased in size, but <50% with improvement in appearance
<b>3. Marked improvement</b>	the lesions decreased in size more than 51%, but <100% with remarkable improvement in appearance
<b>4. Cured</b>	the lesions disappeared completely without recurrence at least 6 months after treatment.

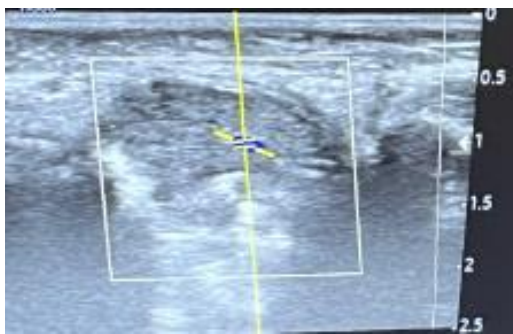
In this case, there was marked improvement at 6 month follow-up. Patient was followed up for a period of 8-12 months with lesion stunted to 0.2X0.2cm (Fig.4)



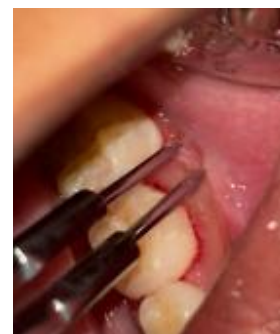**Fig.1 Pre-Op Image**



**Fig.3 – Contrast Enhanced MRI**



**Fig.2 - Color Doppler USG**



**Fig.4 – 8 Month Follow-Up**

## DISCUSSION

Sclerotherapy is a minimally invasive and successful treatment option for VMs.<sup>9</sup> BLM, an antitumor drug discovered in 1966, inhibits DNA synthesis and also affects vascular endothelium through its sclerosing properties. BLM disrupts cell proliferation by cutting the deoxyribonucleic acid (DNA) chain during the S stage of the cell cycle.<sup>2</sup>

In terms of BLM safety, during the follow-up period, there were no clinical symptoms of pulmonary fibrosis, such as central cyanosis, dyspnea or tachypnea, attributed to closely adhering to paediatric safe dosage at 3-week intervals. This is in-line with Ionescu et al.<sup>10</sup>, who verified that, in contrast to intravenous BLM used in chemotherapy, there was no detectable BLM in blood samples obtained from pediatric patients 24 hours following BLM intralesional injections, which also is observed in our study. It is recommended that BLM timing of injections and doses should be documented in medical records, and parents were instructed to inform the anesthesiologist that their child received

BLM, prior to any subsequent surgical procedure. Patients who have received BLM injections within the last 12 months should not receive high concentrations of oxygen in GA because BLM increases lung's sensitivity to oxygen, which can lead to BLM-induced lung toxicity and respiratory failure,<sup>6</sup> however this was not required in our subject.

## CONCLUSION

VMs are one of the rare entities when compared with pathological hamartomas of head and neck regions; therefore guideline protocol for such entities poses a challenge to every maxillofacial surgeon. LFVM in our case occurred in gingiva which is one of the rare sites at an age of 8 years, such a pathology can lead to devastating accidents of haemorrhage costing patient's life. Literature has discussed various modalities of treating it, nevertheless, non invasive to invasive approach is the ladder followed by most. Intralesional injections were first discussed in 1951;<sup>13</sup> and thereafter various agents have been extensively studied, and are now accepted modality

of treating VMs and LFVMs particularly in the cervico-facial region.<sup>6</sup> BLM has been used in our study due to its higher efficacy than other drugs. We observed that scientifically titred dose of BLM, is an

effective method of treating LFVM in gingival region, yet we advocate of such scientific studies to be conducted in larger sample size in a multimodal fashion to validate our conclusions.

## BIBLIOGRAPHY

- Mulliken JB, Glowacki J. Hemangiomas and vascular malformations in infants and children: A classification based on endothelial characteristics. *Plast Reconstr Surg* 1982;69:412-22.
- Bhardwaj A, Gupta S, Moirangthem R, Anant A, Bharadwaj N. Intralesional Bleomycin as Therapeutic Modality for Low-flow Venous Malformations: Treatment on Outpatient Basis. *Int J Head Neck Surg* 2017;8(3):112-117.
- Jan I, Shah A, Beigh SH. Therapeutic effects of intralesional bleomycin sclerotherapy for non-invasive management of low flow vascular malformations - A prospective clinical study. *Ann Maxillofac Surg* 2022;12:151-6.
- Horbach SER, Rigter IM, Smitt JHS, Reekers JA, Spuls PI, van der Horst C. Intralesional bleomycin injections for vascular malformations: a systematic review and meta-analysis. *Plast Reconstr Surg*. 2016;137:244e256.
- Zhang J, Li HB, Zhou SY, Chen KS, Niu CQ, Tan XY, Jiang YZ, Lin QQ. Comparison between absolute ethanol and bleomycin for the treatment of venous malformation in children. *Exp Ther Med*. 2013 Aug;6(2):305-309.
- Arafat S, Abdelmabood AA, Mohamed W, El-Tagy G, El-Swify A. Bleomycin intralesional injections of maxillofacial venous malformations in pediatric patients. *Oral Maxillofac Surg Cases*. 2022 June;8(2)  
<https://doi.org/10.1016/j.omsc.2022.100256>
- Achauer BM, Chang CJ, Vander Kam VM. Management of hemangioma of infancy: review of 245 patients. *Plast Reconstr Surg*. 1997;99:1301Y1308.
- Hassan Y, Osman AK, Altyeb A. Noninvasive management of hemangioma and vascular malformation using intralesional bleomycin injection. *Ann Plast Surg* 2013;70:70-3
- Mishra M, Singh G, Gaur A, Tandon S, Singh A. Role of sclerotherapy in management of vascular malformation in the maxillofacial region: Our experience. *Natl J Maxillofac Surg*. 2017 Jan-Jun;8(1):64-69.
- Ionescu G, Mabeta P, Dippenaar N, Muir T, Fourie P, Shelver G. Bleomycin plasma spill-over levels in paediatric patients undergoing intralesional injection for the treatment of haemangiomas. *S Afr Med J* 2008 Jul;98(7):539-40.
- Abdelaty MH, Badran AI, Aborahma AM, Elheniedy MA, Kamhawy AH. Intralesional injection of bleomycin in the management of low flow vascular malformations: Results and factors affecting the outcome. *J Vasc Surg Venous Lymphat Disord*. 2024 Mar;12(2):101694.
- Churojana A. Bleomycin: An effective drug for intralesional injection treatment of vascular anomalies. *Pharm Pharmacol Int J* 2020;8:38-40.
- Gholizadeh N, Sadrzadeh-Afshar MS, Sheykhbahae N. Intralesional corticosteroid injection as an effective treatment method for oral lesions: a meta-analysis. *Braz. J. Pharm. Sci.* 2020;56:e18077.